

Complex management of resistant oral herpes simplex virus infection following hematopoietic stem cell transplantation: potential role of topical cidofovir

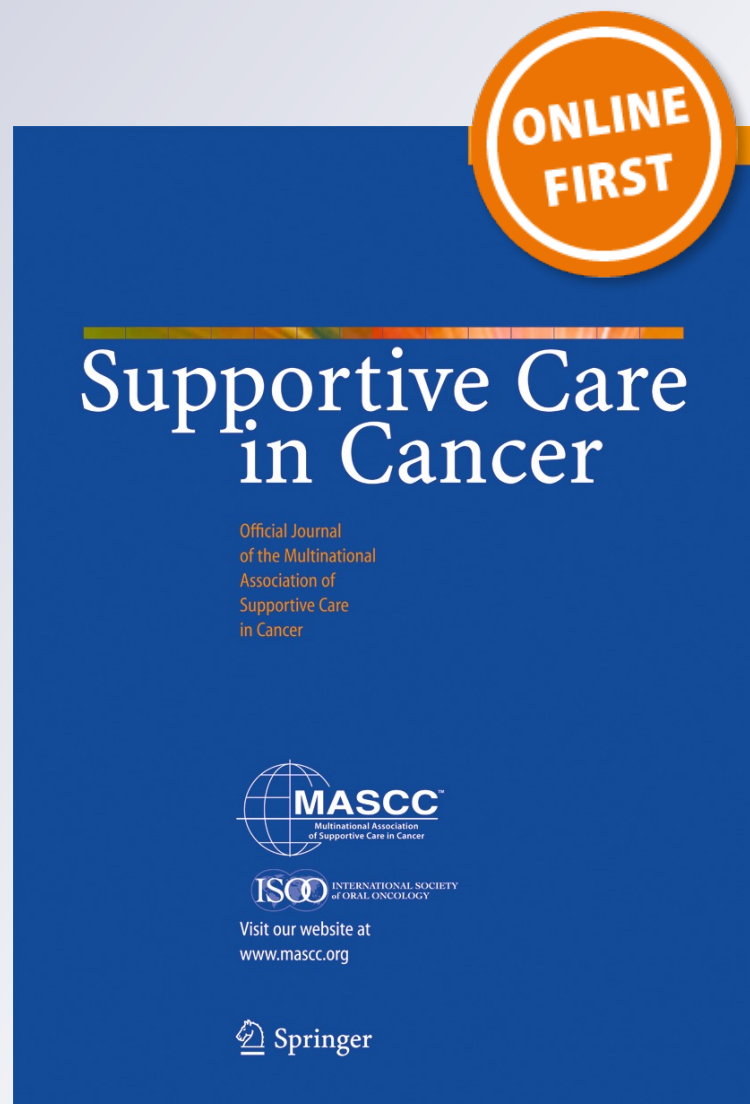
Joel B. Epstein, Sara Gharapetian, Ali R. Rejali, Rachel Zabner, Michael Lill & Dimitrios Tzachanis

Supportive Care in Cancer

ISSN 0941-4355

Support Care Cancer

DOI 10.1007/s00520-016-3264-5



Your article is protected by copyright and all rights are held exclusively by Springer-Verlag Berlin Heidelberg. This e-offprint is for personal use only and shall not be self-archived in electronic repositories. If you wish to self-archive your article, please use the accepted manuscript version for posting on your own website. You may further deposit the accepted manuscript version in any repository, provided it is only made publicly available 12 months after official publication or later and provided acknowledgement is given to the original source of publication and a link is inserted to the published article on Springer's website. The link must be accompanied by the following text: "The final publication is available at link.springer.com".

Complex management of resistant oral herpes simplex virus infection following hematopoietic stem cell transplantation: potential role of topical cidofovir

Joel B. Epstein^{1,2} · Sara Gharapetian² · Ali R. Rejali² · Rachel Zabner² · Michael Lill^{1,2,3} · Dimitrios Tzachanis³

Received: 4 February 2016 / Accepted: 3 May 2016
© Springer-Verlag Berlin Heidelberg 2016

Abstract

Purpose Herpes simplex virus (HSV) infection commonly occurs during the immunosuppression associated with hematopoietic stem cell transplantation (HSCT). Prophylaxis of recurrent infection and management of clinical infection have relied upon acyclovir and congeners. More recently, resistant HSV infection is seen in HSCT and presents new challenges in management. We present a case of HSV following HSCT that provided effective symptomatic management.

Results Oral symptoms and lesions were repeatedly reduced when topical cidofovir was used, strongly supporting the effect of cidofovir used in a host who could not tolerate systemic antiviral medications.

Conclusions Topical cidofovir can provide effective management of symptomatic oropharyngeal HSV while reducing risk of systemic toxicity and drug interaction and represents an additional approach to management for management in medically compromised patients.

Keywords Topical cidofovir · Acyclovir resistant herpes simplex virus infection · Hematopoietic stem cell transplantation

Introduction

Herpes simplex virus (HSV) infections can cause significant morbidity and mortality in patients with hematological malignancies and in patients following hematopoietic stem cell transplant (HSCT). Up to 80 % of adult patients with leukemia are HSV seropositive and the incidence of HSV lesions in patients receiving chemotherapy for acute leukemia is greater than 60 % [1]. Without antiviral prophylaxis, the rate of HSV reactivation in seropositive allogeneic HSCT patients is approximately 80 % [2]. Acyclovir is now commonly used in the HSCT patient population for HSV prophylaxis of seropositive patients and as well as treatment of HSV infection [1].

An increasing incidence of HSV resistant to acyclovir has been reported in the literature [1, 3]. This incidence is low among immunocompetent patients but is as high as 14 % among HSCT recipients [3]. While three different mechanisms may contribute to HSV resistance to acyclovir, a deficiency in thymidine kinase (TK) is the predominant resistance mechanism identified in the majority of HSV strains isolated [1, 3]. Thymidine kinase is an enzyme needed for the activation of acyclovir; thus, acyclovir resistant HSV strains may be susceptible to other antiviral agents that do not require TK for activation. Cidofovir and foscarnet are examples of such antivirals [1, 3].

Both cidofovir and foscarnet are nephrotoxic and the systemic administration of these antivirals can present challenges in patients with impaired renal function [4, 5]. Successful use of topical cidofovir for acyclovir resistant orofacial and perianal HSV lesions has been reported in HIV and HSCT patients [6–11]. Given the lack of a commercially available topical formulation of cidofovir, these formulations have been compounded from the intravenous product. Several gel or oral rinse formulations have been used at a concentration of 0.3–4 % applied once or twice daily for various durations [9–12].

✉ Joel B. Epstein
joel.epstein@cshs.org

¹ Samuel Oschin Comprehensive Cancer Institute, Cedars-Sinai Medical Center, Los Angeles, CA, USA

² Cedars-Sinai Health System, Los Angeles, CA, USA

³ Blood and Marrow Transplant Program, University of California, San Diego, San Diego, CA, USA

The compounded products, while not formally established, have suggested stabilities of >48 h to as long as 30 days [10, 11].

The cost of topical cidofovir can be prohibitive for many patients. Some case reports also indicate that systemic absorption of cidofovir can occur by topical administration and may lead to nephrotoxicity, especially in patients with chronic renal impairment [12]. The optimal concentration and frequency for topical administration of cidofovir is yet to be determined.

We report a case of acyclovir resistant oral HSV treated with cidofovir oral rinse. This case documents the effect of topical cidofovir in a patient with significant symptoms that occurred with oral ulceration and lesion response to topical treatment. IRB expedited review was completed (Pro00041896).

Case report

A 67-year-old male with a history of JAK2-positive myelofibrosis received a 9/10 HLA-mismatched unrelated-donor HSCT. He received reduced intensity conditioning with fludarabine/melphalan. Graft versus host disease (GVHD) prophylaxis was with anti-thymocyte globulin, methotrexate, and cyclosporine. Antiviral prophylaxis was with acyclovir. His immediate post-transplant course was complicated by pulmonary aspergillosis on day +22. He engrafted and was discharged on day +36 post HSCT. After discharge, he had persisting anorexia and weight loss without evidence of GVHD. EBV viremia was detected and he was started on intravenous immunoglobulin (IVIg) and weekly rituximab.

On day +74, he was admitted with fever and painful oral ulcers and was found to have *Campylobacter jejuni* bacteremia and cytomegalovirus (CMV) viremia. He was started on valganciclovir at induction dosing (900 mg BID) for 2 weeks followed by maintenance therapy at 450 mg BID and the CMV viremia resolved. He was cultured for HSV from the ulcerations on the tongue and while HSV was not seen on direct exam, positive culture for HSV type 1 was confirmed by (FISH) fluorescent monoclonal staining. Viral susceptibility was conducted due to persisting/recurrent lesions on two occasions (Table 1).

Due to painful oral ulcerations, he was treated with valaciclovir (1 g po BID) from day +79 to 89. However, during this time, the oral ulcers attributed to HSV progressed to

involve the lower lip and the lower gingiva of the residual ridges in the molar regions bilaterally. He reported considerable mouth pain, affecting his ability to wear dentures and to take food by mouth.

On day +100, he was readmitted to hospital and foscarnet was initiated due to apparent acyclovir resistant oral ulcerations and for recurrent CMV viremia. After 2 weeks, viral cultures remained positive for HSV1/2 from tongue lesions and he was switched to IV ganciclovir on day +114. He subsequently developed fever and worsening oral lesions and was admitted on day +126. Due to increasing oral ulcerations, a biopsy was conducted of a tongue lesion and ganciclovir was switched to acyclovir due to severe myelosuppression on day +132 (Figs. 1–4). The pathologic diagnosis was consistent with HSV and no findings of GHVD were reported (Fig. 5).

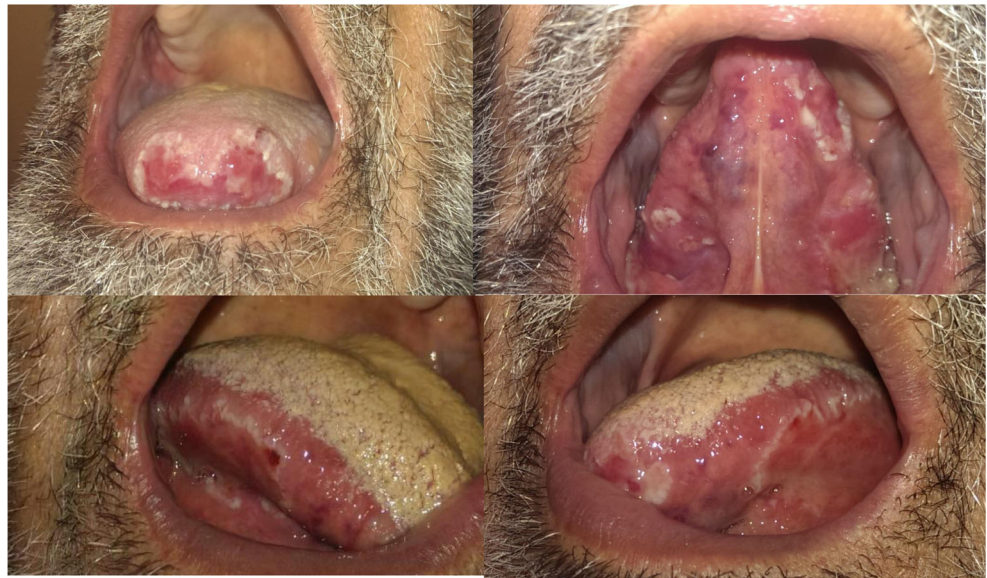On day +136, compounded cidofovir rinse (3 %/15 cm³ swish and spit QID) was started while he continued on foscarnet, white blood cell count (WBC) was 0.4 and absolute neutrophil count (ANC) was 0.2 at that time. Oral ulcers were improved at discharge on day +138. On follow-up day +147, oral lesions were increased in severity resulting in limited oral intake and he admitted to not being compliant with cidofovir rinsing. He was started on total parenteral nutrition as an outpatient and was admitted due to failure to thrive and due to uncertain compliance with use of oral cidofovir rinses. Following readmission and regular twice daily cidofovir topical rinse application, oral lesions and pain again improved. WBC count was 2.5 at that time. The lesions clinically resolved within a week of topical therapy and oral pain resolved. Due to improvement in oral ulcers while on cidofovir BID, the frequency of rinsing was decreased to once daily, however, after 1 week, the oral ulcers and associated pain increased. Cidofovir rinse was resumed BID, and once again the oral ulcers improved and oral pain decreased. His hospitalization was complicated by the development of VRE bacteremia and *Candida krusei* fungemia and renal failure which necessitated discontinuation of foscarnet on day +151. Cidofovir swish and spit was continued. At this time, WBC was 2.6 and ANC was 2.0. An upper endoscopy showed mild chronic gut GVHD and rare herpes virus inclusions in the esophagus, and a small cluster of atypical lymphoid cells, some of which were EBV positive suspicious for evolving post-transplant lymphoproliferative disorder (PTLD). Staging scans for PTLT revealed brain and liver lesions and a biopsy of the liver lesions on day +159 was consistent with monomorphic PTLT, CD20 low positive (attributed to the prior treatment with rituximab for EBV viremia). Immunosuppressants were rapidly tapered and discontinued. On day +171 due to altered mental status and risk of aspiration, cidofovir swish was stopped and the tongue lesions worsened.

On day +178, the patient received weekly IVIG and chemotherapy for PTLT (with Rituximab, Etoposide, Doxorubicin, Vincristine, Cyclophosphamide, Prednisone,

Table 1 Viral sensitivity testing: resistant to acyclovir

	Ref. range	Day +74	Day +139
Acyclovir	No range found	12 resistant	>48 resistant
Foscarnet	No range	25 sensitive	100 sensitive

Figs. 1–4 Oral lesions associated with significant oral pain



and high dose Methotrexate). Post-chemotherapy of the WBC was <0.1 and ANC 0; he developed mucositis with primary involvement of the tongue while his mental status improved. Cidofovir swish was restarted but unfortunately the patient was transferred to ICU with sepsis, bacteremia, and fungemia on day +188. He was intubated and ventilated and eventually expired after terminal extubation on day +189.

Discussion

Oral ulceration due to herpesviruses and antiviral resistance has been reviewed in HSCT [13]. HSV resistance to acyclovir may occur by mutation of the gene for viral thymidine kinase and also due to mutation in the DNA polymerase gene. These isolates may remain susceptible to foscarnet as thymidine kinase is not required for activation of foscarnet. Foscarnet

resistance is associated with multiple mutations of viral DNA polymerase [14, 15].

This case report documents a complex case of severe oral HSV with resistance to acyclovir and that did not respond to acyclovir, valaciclovir, or foscarnet in renal adjusted doses. Renal dosing was required due to elevated creatinine and also due to use of tacrolimus which is also nephrotoxic. Antiviral dosing was acyclovir (400 mg BID), ganciclovir (5 mg/kg q 12 h), and foscarnet (90 mg/kg q 12 h, then decreased to 60 mg/kg post hemodialysis). The complexity of antiviral dosing post HSCT must take renal and marrow function into consideration, as reported in this case. In this case, viral resistance and the altered dosing of antivirals may have led to suboptimal effect. Oral HSV ulcerations and associated symptoms improved when oral cidofovir compounded rinsing was completed BID, and oral lesions and lesions in the proximal esophagitis resolved. Topical application was instituted due to pancytopenia and renal dysfunction, with the goal of delivery of medication to the site of viral activation while limiting systemic exposure. In addition, topical delivery of cidofovir reduces the risk of systemic dosing and therefore potential interaction with systemic agents such as amphotericin B and tacrolimus that may also cause renal toxicity. In this case, cidofovir rinse was effective when used on a regular BID schedule as was seen when compliance was assured and in episodes of repeated flare and improvement in oral lesions. While intubated, the tongue and lip lesions were washed with cidofovir solution and suctioned to prevent aspiration but the repeated response to twice daily topical cidofovir treatment showed the advantage of local effect without systemic risk.

It has been suggested that viral resistance is more common in immunosuppressed patients with cell-mediated immune dysfunction [9, 16, 17]. Intralesional injection of cidofovir was administered in an AIDS patient leading to resolution of

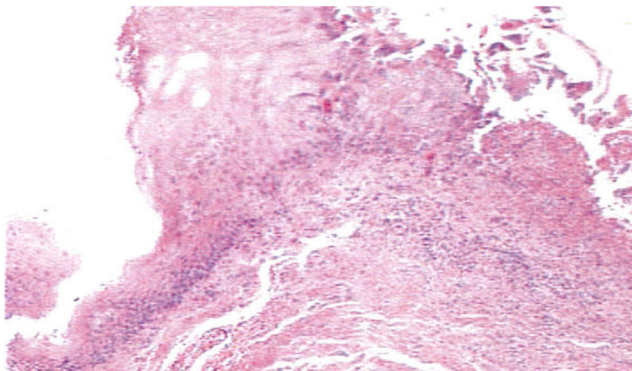


Fig. 5 Low power image of tongue ulceration. Epithelium partly replaced by multi-nucleated keratinocytes with “steel-gray” nuclei and ulceration with fibrin, neutrophils and lymphocytes, superficial perivascular infiltrate and no fungal organisms seen

a nasal ulceration, in a patient with resistant infection, in who the risk of systemic toxicity was felt too high to allow administering systemic cidofovir [18].

Topical cidofovir for HSV infections is supported by case reports for oral, ocular, and skin lesions for DNA viruses including HPV and HSV [19]. Topical cidofovir has been reported effective treatment in CMV and HPV infection in HIV disease [9, 20]. Topical cidofovir has been described in a small number of cases of CMV retinitis in cases with renal abnormalities [21]. A case of chronic HSV ulceration of the vulva in a HIV-positive female resistant to valacyclovir was managed by IV foscarnet and topical cidofovir was effective while immune-reconstitution occurred with highly active antiretroviral therapy (HAART) [22]. A case of perianal skin lesions due to HSV-1 following HSCT was managed with topical cidofovir (1 % gel) with improvement by 2 weeks of treatment and ulcer healing by 2 weeks [6]. Finally, the first oral case report topical cidofovir (3 % in saline) was provided for management of oral herpetic lesions in HSCT setting, where resistance to acyclovir and foscarnet was reported [10]. As systemic absorption may occur with topical cidofovir and in medically compromised patients may result in side effects, dose response should be assessed and tailored to a patient's response to therapy [12].

The case reported here is the second case of symptomatic HSV oral lesions, resistant to acyclovir, valaciclovir, and foscarnet, successfully managed with topical cidofovir. This case shows response on a repeated basis when oral application was provided BID. Oral pain had a significant impact on oral intake and active lesions required TPN, and when associated with readmission to hospital all representing substantial drivers of the cost of care. This case supports consideration for local antiviral exposure to increase dose of antiviral at sites of persisting viral lesions and confirms that topical therapy can enhance control of persisting HSV-induced oral ulceration. Furthermore, this case suggests that topical therapy can be effective in altering the course of HSV infection and may have utility in other herpesvirus infections such as CMV in HSCT patients, while reducing risk of potential systemic toxicity of antiviral agents including possibly myelosuppression and renal toxicity providing additional options in patient care.

References

1. Styczynski J, Reusser P, Einsele H, et al. (2009) Management of HSV. VZV and EBV infections in patients with hematological malignancies and after SCT: guidelines from the Second European Conference on Infections in Leukemia Bone Marrow Transplant 43:757–770
2. Meyers JD, Flounoy N, Thomas ED (1980) Infection with herpes simplex virus and cell-mediated immunity after marrow transplant. J Infect Dis. 142:338–346
3. Morfin F, Thouvenot D (2003) Herpes simplex virus resistance to antiviral drugs. J Clin Virol 26:29–37
4. Product Information. *Vistide [prescribing information]* (2010). Foster City, CA: Gilead Sciences Inc.
5. Product Information. *Foscavir [prescribing information]* (2012). Lake Forest, IL: Hospira Inc.
6. Muluneh B, Dean A, Armistead P, et al. (2013) Successful clearance of cutaneous acyclovir-resistant, foscarnet-refractory herpes virus lesions with topical cidofovir in an allogeneic hematopoietic stem cell transplant patient. J Oncol Pharm Pract 19:181–185
7. Evans KG, Morrissey KA, Goldstein SC, et al. (2011) Chronic acyclovir-resistant HSV-2 ulcer in an immunosuppressed patient treated with topical cidofovir. Arch Dermatol 147:1462–1463
8. Snoeck R, Andrei G, De Clercq E, et al. (1993) A new topical treatment for resistant herpes simplex infections. N Engl J Med 329:968–969
9. Lalezari J, Schacker T, Feinberg J, et al. (1997) A randomized, double-blind, placebo-controlled trial of cidofovir gel for the treatment of acyclovir-unresponsive mucocutaneous herpes simplex virus infection in patients with AIDS. J Infect Dis 176:892–898
10. Sims CR, Thompson K, Chemaly RF, et al. (2007) Oral topical cidofovir: novel route of drug delivery in a severely immunosuppressed patient with refractory multidrug-resistant herpes simplex virus infection. Transpl Infect Dis 9:256–259
11. McElhiney LF (2006) Topical cidofovir for treatment of resistant viral infections. Int J Pharm Compd 10:324–328
12. Bienvenu B, Martinez F, Devergie A, et al. (2002) Topical use of cidofovir induced acute renal failure. Transplantation 73:661–662
13. Van der Beek MT, Loheij AM, Raber-Durlacher JE, van den Borne PA, Wollerbeek R, et al. (2012) Viral loads and antiviral resistance of herpesviruses and oral ulcerations in hematopoietic stem cell transplant recipients. Bone Marrow Transplant 47:1222–1228
14. Saijo M, Suzutani T, Morikawa S, Kurane I (2005) Genotypic characterization of the DNA polymerase and sensitivity to antiviral compounds of foscarnet-resistant herpes simplex virus type 1 (HSV-1) derived from a foscarnet-sensitive HSV-1 strain. Antimicrob Agents Chemother 49:606–611
15. Bestman-Smith J, Boivin G (2003) Drug resistance patterns of recombinant herpes simplex virus DNA polymerase mutants generated with a set of overlapping cosmids and plasmids. J Virol 77: 7820–7829
16. Chen Y, Scieuz C, Garrait V (2003) Resistant herpes simplex virus type 1 infection: an emerging concern after allogeneic stem cell transplantation. Clin Infect Dis 31:927–935
17. Langston AA, Redei I, Caliendo AM, et al. (2002) Development of drug-resistant herpes simplex virus infection after haploidentical hematopoietic progenitor cell transplantation. Blood 99:1085–1088
18. Castelo-Soccio L, Bernardin R, Stern J, Goldstein SA, Kovarik C (2010) Successful treatment of acyclovir-resistant herpes simplex virus with intralesional cidofovir. Arch Dermatol 146:124–126
19. McElhiney LF (2006) Topical cidofovir for treatment of resistant viral infections. Int J Pharm Compd 10:324–328
20. Stier EA, Goldstone SE, Einstein MH, Jay N, Berry JM, et al. (2013) Safety and efficacy of topical cidofovir to treat high-grade perianal and vulvar intraepithelial neoplasia in HIV-positive men and women. AIDS 27:545–551
21. Saunders IM, Lahoti A, Chemaly RF, Trevino C, Westmoreland M, Hosing C (2014) Topical cidofovir-induced acute kidney injury in two severely immunocompromised patients with refractory multidrug-resistant herpes simplex virus infections. J Oncol Pharm Pract 22(2):325–331
22. Griffith-Bauer K, O'Hearn M, Ebst BD (2012). Chronic ulcerative herpes simplex virus infection of the vulva. Case Rep Dermatol 4: 192–196.