



# Oral Surgery, Oral Medicine, Oral Pathology, Oral Radiology, and Endodontology

## **MEDICAL MANAGEMENT AND PHARMACOLOGY UPDATE**

*Editors: F. John Firriolo and Nelson I. Rhodus*

### **Advances in hematologic stem cell transplant: An update for oral health care providers**

Joel B. Epstein, DMD, MSD, FRCD(C), FCDS(BC), FDS RCS(Edin),<sup>a,b</sup>  
Judith E. Raber-Drulacher, DDS, PhD,<sup>c</sup> Affi Wilkins, DDS,<sup>b</sup> Maria-Gabriella Chavarria, DDS,<sup>a</sup>  
and Han Myint, MD, FRCP(Glasgow), FRCP(Edin), FRCPath(London),<sup>d</sup> Chicago, Illinois;  
Leiden, The Netherlands; and Aurora, Colorado  
UNIVERSITY OF ILLINOIS, ILLINOIS MASONIC HOSPITAL, LEIDEN UNIVERSITY MEDICAL CENTER, AND  
UNIVERSITY OF COLORADO HEALTH SCIENCE CENTER

Oral supportive care is critical in the management of patients receiving hematopoietic cell transplantation (HCT). Advances in HCT, such as the use of stem cells isolated from peripheral blood instead of bone marrow, have resulted in more rapid engraftment and thus a shorter duration of pancytopenia. Reduced-intensity conditioning regimens, associated with less toxicity, make HCT available to older patients and patients with comorbidities. These new developments have led to increased transplant rates and an altered spectrum of therapy-related complications, such as mucositis, and to shifts in the prevalence and pattern of occurrence of infections and graft-versus-host disease. The purpose of this paper is to review the main principles of HCT and to update dental providers on new technologies being applied to transplantation that may influence oral complications and oral care. (**Oral Surg Oral Med Oral Pathol Oral Radiol Endod 2009;107:301-312**)

Originally a treatment of last resort, hematopoietic cell transplantation (HCT) is now widely used as a potentially curative procedure for hematologic malignancies as well as a number of other diseases. HCT can serve as a rescue procedure to reconstitute the hematopoietic system when damaged by high-dose chemo/radiotherapy for treatment of malignancy, because hematopoietic stem cells possess the capacity for self-renewal as well as differentiation into all blood cell lineages (Fig. 1). In addition, allogeneic stem cells or their progeny can be used to deliver anticancer immunotherapy. The

number of HCTs now performed is estimated to be 50,000-60,000 annually worldwide (Fig. 2). About 20,000 of these are allogeneic HCTs (in which blood-forming stem cells are derived from a related or unrelated donor), nearly one-half, are to treat acute leukemia. Approximately 35,000 are autologous HCTs (in which a patient is his or her own donor) and are most frequently used for multiple myeloma and non-Hodgkin lymphoma. HCT is also used in the treatment of selected solid tumors and can serve as replacement therapy in patients with congenital immunodeficiency and inborn errors of metabolism or to "reset" the immunologic system in patients with autoimmune disorders.

Oral care is critical in the management of patients receiving HCT. In this article, we provide background information about HCT for the treatment of malignancies, focusing on recent progress, aimed to inform oral care providers. In addition, we explore the potential effect of new developments on oral health and oral care regimens and will identify areas in which more research in this area of oral supportive care is needed.

<sup>a</sup>Professor, Department of Oral Medicine and Diagnostic Sciences, University of Illinois.

<sup>b</sup>Advocate, Illinois Masonic Hospital.

<sup>c</sup>Leiden University Medical Center, Leiden, The Netherlands.

<sup>d</sup>Director, Hematology Malignancies and Blood and Marrow Transplant Program, University of Colorado Health Science Center.

Received for publication Jul 2, 2008; returned for revision Oct 30, 2008; accepted for publication Dec 2, 2008.

1079-2104/\$ - see front matter

© 2009 Mosby, Inc. All rights reserved.

doi:10.1016/j.tripleo.2008.12.006

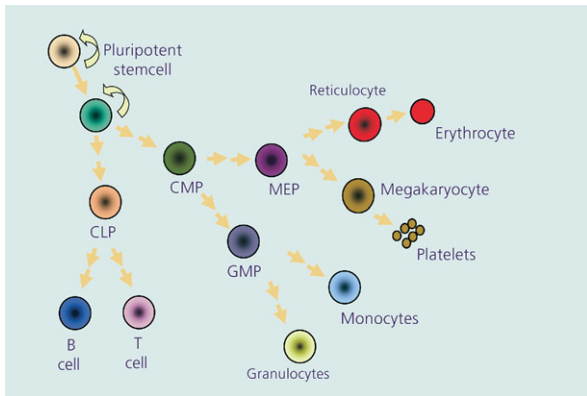


Fig. 1. Hematopoietic stem cell differentiation into different blood cells. *CLP*, Common lymphoid precursor cell; *CMP*, common myeloid precursor cell; *GMP*, common granulocyte/macrophage precursor cell; *MEP*, megakaryocyte-erythrocyte progenitors.

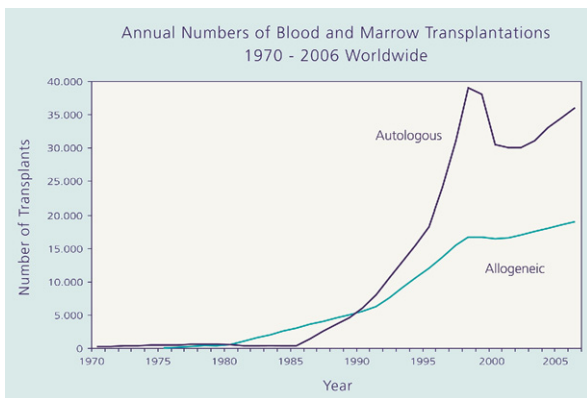


Fig. 2. Annual number of hematopoietic stem cell transplants between 1970 and 2006 worldwide (by courtesy of Center for International Blood and Marrow Transplant Research). There are an estimated 50,000-60,000 hematopoietic stem cell transplants performed annually worldwide. This figure reflects several notable events over the past decade, including the initial enthusiasm and later disappointment about the use of autologous HCT for breast cancer, the availability of targeted nontransplant therapy for chronic myelogenous leukemia (a leading indication for allogeneic HCT), and the increasing use of autologous and allogeneic HCT in older patients.

## HISTORY OF HCT

After the Second World War, fear of subsequent nuclear warfare stimulated increased interest in the effects of ionizing radiation. Bone marrow was recognized as an organ that is sensitive to the effects of radiation, and much effort was directed in developing strategies to treat exposure. Through a series of discoveries in the middle of the 20th century, bone marrow cells were used for the recovery of the human hematopoietic system. In 1949, it was observed that mice could

survive total body irradiation (TBI) at sublethal doses when autologous or syngeneic (derived from a genetically identical twin sibling) marrow cells were transplanted, and that survival was related to hematologic cell recovery.<sup>1</sup> At the same time, it was discovered that radiation could be used to treat leukemia, though it caused irreversible damage to bone marrow cells. In the late 1950s, the first transplants were undertaken. Thomas et al. reported that a patient with end-stage leukemia treated with TBI followed by infusion of her identical twin's marrow had a 3-month remission.<sup>2</sup> As predicted from animal studies, patients who were transplanted with marrow from allogeneic donors developed "secondary disease," now known as graft-versus-host disease (GVHD). Conversely, patients who underwent syngeneic transplantation did not develop significant GVHD, but they died more often from progressive leukemia.<sup>3</sup> From animal studies, it became clear that allogeneic HCT may function as immunotherapy by its graft-versus-leukemia (GVL) effect.<sup>4</sup>

In the early 1960s, the first human leukocyte antigens (HLA) were discovered and the relevance of these antigens in the development of GVHD was established.<sup>5,6</sup> These observations led to the successful clinical application of allogeneic HCT.<sup>7</sup> Since then, great progress has been made in improving the success of HCT. Current indications for HCT are shown in Table I.

## TYPES OF HCT

HCT can be categorized by the source of stem cells used, by the donor of the stem cells, and by the conditioning regimen used to prepare the recipient for HCT.

### Sources of hematopoietic stem cells

In the past, HCT has been called bone marrow transplantation (BMT), because hematopoietic stem cells were exclusively taken from the bone marrow. This procedure requires aspiration from the posterior iliac crest while the donor is under anesthesia. Peripheral blood is now the preferred source for harvesting stem cells in adults. Normally very few stem cells are present in the blood circulation, but there is a dramatic increase in early hematopoietic cells after administration of granulocyte colony-stimulating growth factor.<sup>8,9</sup> Increased numbers of these cells, identified by expression of the surface marker CD34, also appear in the peripheral circulation after recovery from myelosuppressive chemotherapy. Peripheral blood stem cell transplant (PBSCT) has been shown to produce earlier engraftment and recovery of granulocytes and platelets compared with BMT,<sup>10,11</sup> and it is accompanied with reduced early infection and shorter hospitalization.<sup>12</sup> However, allogeneic PBSCT may be associated with a

**Table I.** Current indications for stem-cell transplantation (SCT) (modified from Westbrook et al.<sup>70</sup>)

Disease	Autologous SCT	Allogeneic SCT	Nonmyeloblastic regimens
<b>Leukemia</b>			
Acute myelogenous	+	+	+
Acute lymphocytic	+	+	+
Chronic myelogenous	+	+	+
Chronic lymphocytic	+	+	+
<b>Lymphomas</b>			
Non-Hodgkin	+	+	+
Hodgkin disease	+	+	
Plasma cell dyscrasia		(+) <sup>a</sup>	
Multiple myeloma	+		
Amyloid	+	+	
<b>Solid tumors</b>			+ <sup>b</sup>
Breast cancer	+		
Ovarian cancer	+		
Testicular cancer	+	(+) <sup>a</sup>	
Renal cell cancer			+
Brain tumors			
Neuroblastoma	(+) <sup>a</sup>	+	
Ewing sarcoma	+		+ <sup>b</sup>
<b>Acquired bone marrow disorders</b>			
Severe aplastic anemia	+		
Myelodysplastic syndromes	+		
Myeloproliferative disorders		+	
<b>Congenital disorders</b>	(+) <sup>a</sup>	+	
Sickle cell anemia		+	+
Thalassemia		+	
Fanconi anemia		+	
White cell disorders		+	+
Severe combined immunodeficiency		+	+
Wiskott-Aldrich syndrome		+	+ <sup>b</sup>
Osteopetrosis		+	
Storage diseases		+	+ <sup>b</sup>
<b>Autoimmune diseases</b>		+	
Systemic scleroderma	+		
Rheumatoid arthritis	+		
Systemic lupus erythematosus	+		
Multiple sclerosis	+	(+) <sup>a</sup>	

<sup>a</sup>Tentative indication.

<sup>b</sup>Studies are still in initial stage of clinical trials.

higher incidence of chronic GVHD (cGVHD) and infection with cytomegalovirus (CMV) compared with BMT.<sup>13</sup> Umbilical cord blood (UCB) is an accepted source of stem cells for pediatric transplantation and offers several advantages, such as ease of retrieval with minimal risk to the donor, less stringent HLA-matching criteria without increasing the risk of GVHD, and lower risk of transfer of viruses.<sup>14</sup> However, UCB has been linked to slower engraftment and increased graft fail-

ure,<sup>15</sup> and a limited number of cells that can be obtained from a single umbilical cord hampers the extension of UCB in adults. Recently, pooling UCB from 2 donors whose HLA is closely matched to the recipient has resulted in more rapid engraftment in adults where unrelated donors are unavailable.<sup>16</sup> Despite the difficulties presented, blood sources appear to be a better source of stem cells. Therefore, current practice has moved from using bone marrow to using blood sources to obtain stem cells for transplantation.

**Autologous and allogeneic HCT**

Autologous hematopoietic stem cells in principle are available for every patient; however, transplantation in this setting is provided for marrow reconstitution, and treatment of the cancer is derived entirely from the high-dose conditioning regimen. Furthermore, there is a risk of contamination of the graft with residual malignant cells, which are reinfused into the patient.

Autologous HCT is widely used as curative treatment of chemosensitive malignancies such as non-Hodgkin lymphoma and Hodgkin disease. The current strategy for multiple myeloma is tandem HCT (a combined autologous HCT followed by nonmyeloablative allogeneic HCT). Significant improvements in supportive care, particularly effective management of infection, have improved the safety of autologous HCT. Therefore, strategies to further improve its outcome are concentrated on optimizing techniques to eliminate malignant stem cells from both the patient and the stem cell graft.

In leukemia, allogeneic HCT is the preferred treatment because cancer outcome is derived from high-dose chemotherapy and is accompanied by GVL, an immunologic response against chemo/radiotherapy-resistant malignant cells.<sup>17</sup> Allogeneic stem cell donors may be related (usually a sibling) or unrelated and should have a matching HLA type. Matching is performed on the basis of variability at 3 or more loci of the major histocompatibility complex (MHC) genes that encode for HLA polypeptides. In humans, the terms MHC and HLA are often used interchangeably. The MHC genes are closely linked on chromosome 6 and are inherited as haplotypes (i.e., inherited as a unit). The MHC forms the basis for the ability of the adaptive immune system to distinguish between self and nonself and is involved in initiating immune responses. Based on their structure and function, there are 2 classes of HLA antigens, termed class I and class II. HLA class I antigens include HLA-A, -B, and -C and are found on nearly all cells of the body, whereas class II HLA-DR, -DQ and -DP antigens are typically found on cells of the immune system. The availability of an identical twin (syngeneic) donor is less than 1%, and siblings

have a ~25% chance of being genotypically HLA identical (i.e., inheriting the same paternal and maternal MHC genes: a 2-haplotype match). It may also be possible to identify individuals within families (e.g., a parent, uncle, aunt, cousin) who share only 1 haplotype which is identical by descent and are phenotypically matched for the nonshared haplotype. The lack of HLA-identical related donors has stimulated the development of large data banks of volunteer unrelated donors. Great progress has been made in HLA-typing technology and, whenever possible, unrelated donors are completely phenotypically matched for critical HLA class I and II antigens. This level of matching does not necessarily mean that the donor and the recipient are matched for all epitopes on these molecules nor for the numerous other polymorphic genes within the MHC. In addition, even in closely related donors, mismatched minor histocompatibility antigens (mHags), encoded by genes outside the MHC in the recipient, that are recognized as antigens by donor T cells may induce immune responses resulting in graft rejection and GVHD.<sup>18</sup> For this reason, immunosuppressive regimens are required in allogeneic HCT even when grafts are derived from donors that are genotypically HLA identical.

### Conditioning regimens

The objective of myeloablative preparation before transplantation is both to eradicate malignant cells and, in allogeneic transplantation, to induce immunosuppression that permits engraftment. TBI combined with cyclophosphamide has been the standard preparative regimen since the 1980s, but the toxicity of TBI, particularly in children, has resulted in the development of radiation-free regimens. Myeloablative HCT is associated with considerable toxicity to mucosal barriers and induces profound myelosuppression which puts the patient at risk for serious infectious complications until engraftment. In the late 1990s, a better understanding of GVL biology led to preparative regimens that involve less intensive conditioning radio/chemotherapy and are thus less toxic than myeloablative regimens. Unlike traditional conditioning, these new regimens are primarily immunosuppressive to enable engraftment of the transplanted donor cells, and depend on the graft to eradicate cancer. These regimens have been divided into truly nonmyeloablative regimens (in which the bone marrow will recover even without HCT) and reduced-intensity conditioning regimens (RIC) in which chemotherapeutic drugs are used that are less cytotoxic than myeloablative regimens but are used in higher doses than in a nontransplant setting.<sup>19,20</sup> For reasons of simplicity we will use the term RIC in this article (Table II). RIC transplants are associated with

**Table II.** Impact of advances in hematologic transplants

<i>Nonmyeloablative transplants (minitransplants)</i>
Hematopoietic growth factors
Advances in antimicrobial prophylaxis
Reduced prevalence/severity of oral mucositis
Change in spectrum of infection:
Increased fungal infection, reduced <i>Candida albicans</i>
Reduced <i>Herpes simplex</i> infection, increased cytomegalovirus infection
Increased graft versus host disease

less morbidity and mortality compared with myeloablative regimens in the first 3 months after transplant, but more patients may develop complications thereafter. RIC transplants can be conducted in patients previously not eligible for myeloablative protocols because of their age or medical condition.<sup>21,22</sup>

### DONOR LYMPHOCYTE INFUSION

The concept of donor lymphocyte infusion (DLI) contributed to a paradigm shift in which myeloablative conditioning is no longer deemed to be necessary for the eradication of tumor cells. In early studies, DLI alone was shown to induce transient remission in patients with relapsed chronic myeloid leukemia (CML), even without previous HCT.<sup>23</sup> Today, DLI may be used to induce durable remission in patients with early-stage relapsed CML after allogeneic HCT. DLI is only moderately effective for relapse of acute myeloid leukemia, with 15%-40% of patients achieving complete remission, and is rarely successful in patients with relapsed acute lymphoblastic leukemia. Multiple myeloma patients have response rates to DLI of 40%-45%, suggesting a benefit in relapsed disease. Complications of DLI include acute and chronic GVHD, though GVHD after DLI may be easier to control than HCT-induced GVHD. In contrast to myeloablative transplant, RIC preserves the recipient's hematopoietic system to various degrees, and transplanted stem cells coexist with residual host lymphocytes and marrow cells (mixed chimerism). This situation may cause graft rejection (Table III). DLI can successfully convert chimerism to full donor type. Although DLI remains the mainstay of adoptive immunotherapy after HCT,<sup>24</sup> new approaches are being developed, allowing more targeted treatment of relapsed or persistent leukemias by using leukemia-specific cytotoxic T-cells.<sup>25,26</sup> Epstein-Barr virus-specific cytotoxic T cells are being used to treat post-transplant lymphoproliferative disorders, and likewise, CMV-specific T cells are being used to treat viruses that affect patients after HCT.



**Table III.** Reduced-intensity (RI) conditioning regimens and their risks of graft-versus-host disease (GVHD) and treatment-related morbidity and mortality (TRM) (modified from National Cancer Institute<sup>69</sup>)

<i>RI conditioning regimen</i>	<i>Risk of GVHD</i>	<i>Risk of TRM</i>
Busulfan + FLU + ATG	34	15
Thiotepa + cyclophosphamide	25	14
TBI 200 cGY	50	15
Melphalan + FLU + CAMPATH	~0	16

**SELECTED COMPLICATIONS AFFECTING THE ORAL CAVITY**

**Mucositis**

Mucositis is induced by radiation therapy and/or chemotherapy and is characterized by mucosal damage ranging from mild inflammation to extensive ulceration, which may affect the oral cavity and other parts of the alimentary tract. In patients treated with myeloablative HCT, oral mucositis (OM) most frequently affects nonkeratinized mucosal surfaces, such as ventral and lateral tongue, floor of mouth, soft palate, buccal mucosa, and inner side of the lips. Typically, OM peaks between post-transplant days 6 and 12 and begins to resolve by day 14-18. OM is one of the most debilitating acute complications of myeloablative HCT from the patient’s perspective, because it accompanied with pain and dysphagia and affects food and oral medication intake.<sup>27</sup> Ulcerative mucositis is associated with potentially life threatening infection and leads to an increased demand on health care resources.<sup>28,29</sup>

Mucosal damage is also considered to be associated with the development of acute GVHD. The incidence of OM has been estimated to range from 75% to 100% after myeloablative conditioning regimens,<sup>30</sup> and the preparative regimen is an independent risk factor for the severity and the pattern of OM.<sup>31</sup> Robien et al. found TBI-containing conditioning regimens, being overweight, and a genetic polymorphism associated with increased methotrexate toxicity to be risk factors for OM in patients receiving allogeneic HCT for myeloid leukemia.<sup>32</sup> Methotrexate as prophylaxis for GVHD has also been associated with a significantly higher severity and duration of OM compared with other immunosuppressive drugs.<sup>33</sup>

Little information is available on the prevalence and severity of OM after RIC regimens, although the incidence and severity of OM is expected to be lower. Vela-Ojeda et al. reported in a study comparing myeloablative versus RIC regimens for allogeneic HCT in patients with leukemia that severe mucositis developed in 32% and 7% of those patients, respectively.<sup>34</sup> Prospective clinical studies with OM as a primary end

point are needed to clarify the prevalence and severity of OM associated with different RIC regimens. In such studies, effort must be taken to distinguish between OM and oral herpes simplex virus (HSV) infection, because HSV reactivation may frequently occur after potent immunosuppressive RIC regimens unless antiviral prophylaxis is provided.

**Infection**

Infections, including those from oral sources, are a frequent complication of HCT. Risk factors include the underlying malignant disease, the medical condition of the patient, the presence of chronic or latent infections, the type of transplant, the source of stem cells, the use of antimicrobials, mucosal barrier loss, and the development of GVHD. There are 2 main mechanisms that play a role in the risk for infection. One depends on nonspecific defenses such as the integrity of surface barriers, which may be damaged by intensive conditioning regimens. In addition, the use of indwelling venous catheters contributes to the infection risk. The other major defence against infections is the immune system, which has a nonspecific and a specific component. Nonspecific protection results from activity of granulocytes, monocytes, macrophages, natural killer (NK) cells, T cells, and complement. The specific immune system cannot operate independently from the nonspecific immune system, because cells from the nonspecific immune system are required to present antigen in the context of HLA before a specific immune response can be mounted.<sup>35</sup> Virtually all components of the immune system are deficient after HCT.

Uncomplicated recovery starts with healing of the mucosal tissues and recovery of granulocytes and NK cells about 2 weeks after myeloablative conditioning. T-Cell and B-cell immune responses against viral, bacterial, and fungal organisms may be suppressed for a prolonged period of time, particularly if GVHD develops after allogeneic HCT. There is evidence that the oral microflora is a major source of systemic infection particularly in the setting of OM.<sup>36-39</sup> Disease, drugs, and hospitalization affect the composition of the microbial flora and defence mechanisms of oral mucosal tissues, including decreased salivary production deficient in immune proteins (see subsequent section). In such an environment, it is extremely important to treat preexistent clinical oral infection, reduce the oral microbial load by interventions in the pretreatment phase, and avoid accumulation of dental plaque by maintaining good oral hygiene after HCT. OM is acknowledged to be the principal risk factor for bacteremia due to viridans streptococci<sup>40</sup> and coagulase-negative staphylococci.<sup>41</sup> In addition, oral mucosal infections may be associated with a wide variety of other microorganisms,

including anaerobic bacteria, fungi, and viruses, virtually all of which may give rise to systemic infectious complications. Current management for *Candida* infections has reduced systemic candidiasis, although oropharyngeal and esophageal infection remains a common complication of treatment with potentially serious consequences. Aspergillosis and other fungal pathogens have become of increasing concern. Late infection with CMV is also seen more frequently. The time of occurrence and appearance of the lesions, including size, distribution, and color, may contribute to the differential diagnosis.<sup>42</sup> However, it is typically difficult to diagnose infections based on clinical presentation alone, and coexistent oral conditions such as mucositis and GVHD increase the difficulty of diagnosis.

In addition to infections related to the oral mucosa, chronic infections associated with the dentition may give rise to complications during myelosuppression. These infections typically involve the dental pulp/periapical area, impacted teeth, and the periodontium. Periodontal infections, in particular, may represent a source of systemic infection in neutropenic patients.<sup>43</sup> Nevertheless, the contribution of chronic periodontitis to systemic infections is probably underestimated, because these infections can be easily overlooked, particularly during neutropenia when local signs and symptoms of infection are reduced.

### Oral bleeding

Oral bleeding may occur during profound thrombocytopenia either due to active disease in patients with acute leukemia at diagnosis or secondary to chemotherapy-induced myelosuppression. When the platelet count is  $>40,000/\mu\text{L}$ , clinically significant bleeding is rare, whereas at counts  $<10,000/\mu\text{L}$ , the risk of spontaneous oral hemorrhage increases significantly.<sup>44</sup> Although bleeding does not appear to be directly associated with OM, it is plausible that ulcerative lesions increase the tendency to bleed when submucosal blood vessels are exposed to trauma. In addition, HSV infection can significantly increase the bleeding risk. Similarly, gingival inflammation contributes to the risk of gingival bleeding. Although profound thrombocytopenia is the most common reason for oral hemorrhage, other mechanisms including disseminated intravascular coagulation may contribute to oral bleeding.

### Graft-versus-host disease

Despite advances in HCT and immunosuppressive therapy, GVHD remains a major cause of morbidity and mortality in allogeneic HCT recipients.<sup>45</sup> GVHD is caused by reaction of donor-derived immunocompetent cells against the recipient's tissues. Severity relates to differences in histocompatibility (e.g., HLA and

mHag), the number of donor T cells infused, and use of immunosuppressant medications. Traditionally, acute GVHD (aGVHD) and cGVHD were distinguished by the time of onset;  $<100$  days after stem cell infusion was considered to be acute and  $>100$  days chronic. However, a clear distinction between aGVHD and cGVHD based on its time of occurrence is no longer valid in the era of RIC transplantation. Observations in patients transplanted with RIC regimens or in patients receiving DLI at various time intervals after transplantation indicate that manifestations of aGVHD may appear several months after HCT. Furthermore, clinical characteristics of cGVHD can occur as early as 50 days after transplantation.<sup>46</sup> Therefore the current consensus is to define GVHD, whether acute or chronic, based on its clinical presentation rather than the timing of development.<sup>47</sup> Acute GVHD is characterized by apoptosis and necrosis affecting the skin, gastrointestinal tract, and liver. Clinically, this may present as skin rashes, diarrhea, nausea, vomiting, and jaundice. In the oral cavity, lesions are often painful, erythematous, ulcerative, and desquamative.<sup>48</sup>

The pathophysiology of aGVHD is considered to be a 3-step process in which the innate and the adaptive immune systems interact: 1) GVHD is initiated when donor T cells are activated by host antigens expressed in tissue damaged by conditioning regimens, or activation may be mediated by lipopolysaccharide present on the cell surface of gram-negative bacteria that have translocated through damaged mucosa; 2) inflammatory cytokines produced by donor T cells induce proliferation and differentiation of various effector cells, including antihelper and cytotoxic T cells, macrophages, and NK cells; and 3) in the effector phase, these cells cause damage to target tissues.<sup>49</sup> Alloreactive T cells are thought to drive the manifestations of cGVHD; however, the exact role of specific T-cell subsets and the interaction with B cells remain under investigation.

About one-half of allogeneic HCT recipients develop cGVHD, which may affect a broad range of tissues, including the skin, gastrointestinal tract, eyes, lungs, female genital tract, and liver. Chronic GVHD represents an inflammatory and fibrotic process which has features reminiscent of various autoimmune/immunologic disorders. Chronic GVHD may be preceded by aGVHD.<sup>50</sup> Oral involvement was found in about 70% of PBSCT recipients and in 53% of BMT recipients with cGVHD,<sup>51-53</sup> whereas Flowers et al.<sup>13</sup> reported the mouth to be the most frequently affected site in BMT recipients and the second most affected site after PBSCT. It typically presents as lichenoid changes with varying degrees of erythema, white striations and plaques, painful ulceration, hyposalivation, mucocoeles, gingival atrophy, hypersensitivity of teeth and oral mu-

cosa, and sclerosis resulting in limited mobility of oral tissues, all of which contribute to an effect on oral function and oral care.<sup>54</sup> The combination of difficulty with oral hygiene and dry mouth may create a potent cycle increasing infection risk, including candidiasis and caries. In addition, cGVHD and its treatment induce immunosuppression which increases infection risk.

It was hoped that RIC regimens would lead to less severe GVHD, because these regimens induce less mucosal toxicity and may be associated with a reduced production of proinflammatory cytokines (cytokine storm). However, there are no data indicating that RIC transplant reduces the risk for GVHD.<sup>55,56</sup> An important confounding factor may be the increased age of patients treated with these regimens, because increased age is associated with more frequent and more severe GVHD. In a pilot study, Elad et al. found the incidence of oral aGVHD after RIC transplant to be significantly lower than after myeloablative conditioning, at least in the first 100 days after transplant.<sup>57</sup>

### Salivary changes and dry mouth

Diminished salivary flow and xerostomia (the subjective feeling of a dry mouth) is common after HCT. Patients report oral dryness as the second most distressing symptom at discharge for transplant and at 1 year after HCT.<sup>58</sup> Saliva contains many components of the nonspecific and specific immune response, including proteins with antimicrobial, immunomodulatory, and antiinflammatory activity, which are crucial for local host defences.<sup>59,60</sup> In addition, saliva is a reservoir for ions that facilitate remineralization of the teeth. In a recent study, salivary samples from patients undergoing allogeneic HCT with myeloablative conditioning as well as RIC, secretory IgA was found to be decreased 1 month after transplant and returned to pretransplant levels after 6 months in both conditioning regimens. The IgA levels remained low in patients with aGVHD.<sup>61</sup>

### Taste alterations

Patients receiving myeloablative as well as RIC preparative regimens often experience distressing alterations in taste (dysgeusia) or a reduction in taste sensation (hypogeusia, ageusia). In addition, cyclosporine and tacrolimus may induce taste changes that may be a metallic, salty, sweet, sour, or bitter taste or no taste at all. Taste dysfunction can last from days to months but usually recovers.<sup>62</sup> Oral GVHD has also been associated with taste dysfunction.<sup>65</sup> The exact etiology for taste alterations in cancer patients is unknown but may be associated with several factors, including the tumor itself, direct toxicity of cytotoxic agents to replicating

taste buds, neurotoxicity, hyposalivation, infection, immune-related GVHD damage directed against taste receptors, and psychologic changes, including conditioned food aversions. Taste dysfunction can result in emesis, reduced food intake, and weight loss and can significantly affect quality of life.

### Second malignancies

With increased numbers of patients surviving long term, late effects of HCT have become of increasing clinical importance. Among these late effects, second malignancies have been recognized.<sup>63</sup> Previous exposure to chemo/radiotherapy, alterations in immune function, GVHD, and GVHD therapy collectively contribute to risk for second malignancy. Second malignancies after HCT include lymphoproliferative disorders, hematologic malignancies, and solid tumors. Hematologic malignancies and lymphoproliferative disorders are most frequently observed early in the post-transplant period.<sup>64</sup> Solid tumors may develop many years after HCT. In the vast majority of cases, oral tumors are squamous cell carcinomas (SCC). Several authors have described cases of SCC at oral and skin sites previously affected by cGVHD-related inflammatory processes, suggesting that cGVHD is a risk factor.<sup>65,66</sup> In addition, prolonged immunosuppressive therapy may contribute to the risk of developing SCC. Long-term follow-up of HCT patients is recommended to detect cancers at an early stage, and patients should be informed of cancer risk and educated to avoid life styles, such as cigarette smoking, that can potentiate the risk of developing oral SCC.

### Osteoporosis and bone necrosis

Conditioning regimens, particularly those including irradiation, may induce endocrine function abnormalities that may affect oral health. Long-term corticosteroid therapy may contribute to the loss of bone density, which may affect the alveolar bone and temporomandibular joints and may be associated with an increased risk of avascular necrosis of bone, particularly weight-bearing bone.<sup>67</sup> HCT recipients may have received bisphosphonates for various indications, which may lead to musculoskeletal pain and increased risk of osteonecrosis of the jaw.<sup>68</sup>

### ORAL SUPPORTIVE CARE

Providing oral supportive care to HCT patients is part of "good clinical practice." The main goals of the oral/dental management are to prevent infections during periods of neutropenia and to reduce oral side effects associated with HCT. Key elements of reaching these goals include reducing the oral microbial load by treating preexistent oral/dental infections, maintaining good oral hygiene, and reducing trauma.

**Table IV.** Oral supportive care during the different phases of hematopoietic stem cell transplantation (HCT); close cooperation between multiple disciplines is mandatory during all of these phases

Preconditioning phase	<ul style="list-style-type: none"> <li>• Oral/dental evaluation (clinical and radiographic)</li> <li>• Reduce oral bacterial load</li> <li>• Eliminate foci of infection</li> <li>• Eliminate sources of trauma</li> <li>• Educate patient and family (importance of oral care, dietary counseling)</li> <li>• Consider cryotherapy and Palifermin in myeloablative HCT</li> <li>• Consider prophylaxis for streptococcal, viral and fungal infection</li> </ul>
Early post-HCT: neutropenic phase/engraftment	<ul style="list-style-type: none"> <li>• Perform good oral hygiene measures; chlorhexidine may be indicated for plaque reduction and management of fungal infection</li> <li>• Keep oral tissues, including lips, moist</li> <li>• Avoid trauma (hard, hot, or spicy food, wearing of dentures, partial prostheses, or orthodontic appliances)</li> <li>• Assess severity of mucositis and pain, and provide adequate pain management</li> <li>• Assess oral cavity for infection, and culture suspect lesions</li> <li>• Consider an agent with anaerobe activity when a patient with periodontitis develops neutropenic fever</li> <li>• Assess oral cavity for bleeding</li> <li>• Consider sugarless chewing gum, salivary substitutes, or sialogogues in patients with oral dryness</li> </ul>
Late post-HCT: immune reconstitution phase	<ul style="list-style-type: none"> <li>• Assess oral cavity for infection, and culture suspect lesions</li> <li>• Assess oral cavity for GVHD in allogeneic HCT recipients</li> <li>• See patients with chronic GVHD regularly; consider local therapies</li> <li>• Reinforce oral hygiene</li> <li>• Perform invasive dental procedures after consultation with the hematologist</li> <li>• Consider sugarless chewing gum, sialogogues, salivary substitutes, fluorides, and remineralization products in dentate patients with oral dryness</li> </ul>
Long-term follow-up	<ul style="list-style-type: none"> <li>• Be aware of oral lesions associated with tumor relapse</li> <li>• Monitor oral cavity for oral complications (GVHD, hyposalivation, infections, caries and periodontal risk, second malignancies)</li> <li>• Be aware of oral lesions associated with tumor relapse</li> <li>• Be aware of jaw osteonecrosis risk in patients treated with bisphosphonates</li> <li>• Assess for dental and craniofacial growth disturbances in pediatric HCT recipients</li> </ul>

GVHD, Graft-versus-host disease.

Oral supportive care for HCT recipients can be divided into different phases: preconditioning, early post-transplant, late post-transplant, and long-term follow-up phases (Table IV). Oral care during these phases should be monitored and provided by informed and experienced dental practitioners that are in close communication with the oncology team. All members of the health care team should understand the nature of the medical condition and planned treatment and needs for oral/dental care. Close consultation is needed to perform appropriate oral and dental care in a timely fashion in relation to cancer therapy, blood counts, and systemic medications at all phases, i.e., before, during, and after transplant. It is important to realize that allogeneic HCT recipients may be immunocompromised for prolonged periods and that invasive dental procedures may put these patients at risk and outcomes of the procedures may be compromised. There are excellent publications for health care professionals and patients that provide detailed information about the rationale and practical issues of the prevention and treatment of

oral complications during the different phases of HCT.<sup>69-71</sup>

During treatment, the patient often experiences morbidity due to mucositis, oral infection, oral bleeding, dry mouth, and infection may increase risk of mortality. The patients' oral hygiene regimen should be encouraged and reinforced throughout the cancer therapy.<sup>72</sup> Advances in the understanding of the pathobiology of mucositis will lead to the extension of the therapeutic arsenal, and presently promising agents are under experimental and clinical study. Clinical guidelines on the management of mucositis were recently updated.<sup>73,74</sup> Cryotherapy and human keratinocyte growth factor may be considered for the prevention of OM in the setting of myeloablative HCT (Tables II-IV).

Patients should minimize wearing dentures, to reduce tissue trauma and because oral prostheses are colonized with microbial pathogens.<sup>75</sup> Clinical diagnosis of OM, candidiasis, or other fungal infections and viral reactivation is critical. Researchers have investi-



gated the oral colonization of *Candida spp.* in the HCT patient and the impact of systemic antifungals. Systemic antifungal prophylaxes were administered to all patients in addition to routine chlorhexidine oral rinses, and *Candida* colonization was seen in 31% of patients. Topical polyenes reduced oral colonization in patients on systemic fluconazole prophylaxis during transplant.<sup>76</sup> In another HCT trial, chlorhexidine alone resulted in significantly decreased *Candida* colonization compared with patients using chlorhexidine and nystatin, a result thought to be due to interaction between these 2 agents.<sup>77</sup> Oropharyngeal colonization by *Candida albicans* occurred despite the use of systemic and topical antifungals.<sup>78</sup> Increasing numbers of infections with nonalbicans *Candida spp.*, including aspergillus, mucor, and fusarium infections are developing in immunocompromised HCT patients. Therefore microbiologic documentation is mandatory, and systemic therapy must be instituted promptly owing to high risk for morbidity and mortality.<sup>79</sup> The prevalence of oral HSV lesions has been considerably reduced with the use of prophylactic acyclovir and, more recently, valacyclovir regimens. Topical therapy alone is generally not efficacious in the immunocompromised patient. The risk of HSV reactivation remains high until immune reconstitution occurs. Furthermore, viral cultures are essential to accurate diagnosis but may not distinguish between clinical infection and viral shedding. Assays that produce more rapid results, including direct immunofluorescence, shell vial testing, and specific immunoassay for HSV antigen and/or biopsy, may be useful.

Varicella zoster virus (VZV) spreads via dermatome distribution, although in immunocompromised patients multiple dermatomes or a more widespread distribution of lesions can be seen. Orofacial VZV lesions are typically observed several weeks or months after cessation of chemotherapy. This is in contrast to HSV, which often occurs during chemotherapy and within 2-3 weeks after chemotherapy is discontinued. For reasons that are not entirely clear, the period of increased risk for reactivation of VZV essentially extends from ~3-12 months after transplant, with allogeneic transplant recipients being at highest risk. Acyclovir, valacyclovir, and famciclovir are currently the primary drugs used for treatment. Infections caused by nonherpes viruses are also relatively common in HCT recipients, with the risk of infection apparently increasing with the degree and duration of immunosuppression. Oral lesions caused by adenovirus and human papilloma virus (HPV) may develop. Patients with cutaneous HPV lesions may demonstrate oral lesions. These lesions can present as hyperkeratotic verrucoid lesions or as flat acuminata-like lesions. Restoration of immune function may result in a disappearance of the oral

mucosal lesions, but laser surgery or cryotherapy are typically used to remove oral HPV lesions when medically or cosmetically necessary. Intralesional injections of interferon-alpha may prove to be effective for recurrent lesions.<sup>69</sup>

Oropharyngeal pain due to mucositis is of considerable concern for patients and is the primary reason HCT patients receive opioid analgesics during treatment. Pain management, including use of topical therapy as well as systemic analgesics, and adjuvant medications and approaches are needed for effective pain management.<sup>80</sup>

Many of the recommendations followed during the early post-HCT phase should be followed also in subsequent phases (Table I). Management of GVHD typically consists of cyclosporine or tacrolimus with corticosteroids. Because these regimens have a high failure rate, alternative options for prevention and treatment (e.g., graft manipulation, antithymocyte globulin, monoclonal antibodies, growth factors, extracorporeal photopheresis, mycophenolate mofetil, low-dose methotrexate, sirolimus) are sought. In oral cGVHD, systemic therapies may be combined with topical agents.<sup>50,54</sup> Local measures, including the application of immunosuppressive agents (e.g., steroids, tacrolimus, cyclosporine, azathioprine) may be sufficient for control of oral involvement. It is not uncommon for oral symptoms to persist or to be the only site of involvement, but well designed controlled studies are clearly needed to assess treatment outcomes. Potential drug interactions may occur in patients on tacrolimus or sirolimus, and familiarity with transplant protocols and close communication between the oncologist and the dental professional is essential. It is advisable to see patients with oral cGVHD regularly to detect oral complications early and to implement and maintain an oral care plan, including the maintenance of good oral hygiene, according to their individual needs.

Reduced saliva production increases the risk of dental demineralization, caries, oral mucosal injury, and mucosal infection (candidiasis) and affects taste. Recommended treatment for hyposalivation includes systemic sialogogues (pilocarpine hydrochloride, bethanechol, Evoxac).<sup>81</sup> Nonpharmacologic treatments include sugarless gum or candies, popsicles, frequent water sipping, bland nonalcohol-based mouthwashes, and water- or aloe-based lip balm. To prevent dental caries and demineralization, patients should receive nutritional counseling, use daily fluoride gel in custom trays or brush-on high-potency fluoride applications during and after cancer therapy, remineralizing products, and, for patients with high-risk cariogenic flora, chlorhexidine-containing products.

## CONCLUSION

The field of HCT is developing rapidly. New treatment strategies warrant continuous adaptation of oral care regimens to the changing scope of oral complications. Studies on the pathogenesis of acute and chronic oral complications are key elements of prevention and treatment. A better insight should be obtained in the epidemiology of these complications and in its risk factors. Clinical research specifically directed at adult and pediatric HCT recipients and including significant numbers of patients should be performed to develop evidence-based recommendations and form a solid base for the recognition of the medical necessity of oral and dental supportive care. Providing oral supportive care in these patients requires an understanding of HCT procedures and complications and close cooperation between multiple disciplines.

Advances in HCT technology, including RIC protocols, have led to a shift in the pattern of complications and made HCT available to older patients. Whereas early transplant complications, such as the severity and duration of OM, as well as the risk of infection, may be decreased after RIC regimens compared with after myeloablative conditioning, this does not mean that oral/dental care before and during transplant is superfluous in these patients. On the contrary, eliminating oral infection before HCT remains important. Infection may exacerbate GVHD, and invasive dental procedures may be contraindicated for an extended period of time after transplant. If GVHD develops after transplant and/or DLI, there is a clear need for input from dental professionals in the diagnosis and management of oral GVHD and its sequelae.

The number of long-term HCT survivors is increasing. This is associated with a need for monitoring late oral complications, such as second malignancies, osteonecrosis of the jaw, and complications that are specific to HCT performed during childhood, such as disturbances of craniofacial growth and tooth development.<sup>82-84</sup>

There is a trend to perform RIC transplants in outpatient settings, which underscores the need for the general dental practitioner to be cognizant of pretransplant dental management needs, preventative strategies, complications that may develop, and indications and contraindications for dental treatment. Education in basic aspects of oncology-specific oral care should be part of the curriculum of all health care providers who may encounter cancer patients in their clinical practice. Dentists must continue to inform themselves of their role in the care of these patients.

Sciences, University of Illinois, Chicago, for editorial assistance.

## REFERENCES

- Jacobson LO, Simmons EL, Marks EK, Robson MJ, Bethard WF, Gaston EO. The role of the spleen in radiation injury and recovery. *J Lab Clin Med* 1950;35:746-70.
- Thomas ED, Lochte HL, Jr, Lu WC, Ferrebee JW. Intravenous infusion of bone marrow in patients receiving radiation and chemotherapy. *N Engl J Med* 1957;257:491-6.
- Copelan EA. Hematopoietic stem cell transplantation. *N Engl J Med* 2006; 354:1813-26.
- Barnes DW, Loutit JF. Treatment of murine leukaemia with x-rays and homologous marrow II. *Br J Haematol* 1957;3: 241-52.
- Dausset J. Iso-leuco-anticorps. *Acta Hematol* 1958;20:156-66.
- Jansen J. Jon van Rood: Pioneer at the crossroad of human leukocyte antigens and transplantation. *Trans Med Rev* 2006; 21:159-63.
- Thomas ED, Fefer A, Buckner CD, Storb R. Current status of bone marrow transplantation for aplastic anemia and acute leukemia. *Blood* 1979;49:671-81.
- Appelbaum FR. The current status of hematopoietic stem cell transplantation. *Ann Rev Med* 2003;54:491-12.
- Riley RS, Idowo M, Chesney A, Zhao S, McCarthy J, Lamb LS, et al. Hematologic aspects of myeloablative therapy and bone marrow transplantation. *J Clin Lab Anal* 2005;19:47-79.
- Elfenbein GJ, Sackstein R. Primed marrow for autologous and allogeneic transplantation: a review comparing primed marrow to mobilized blood and steady state marrow. *Exp Hematol* 2004;32:327-39.
- Beyer J, Schella N, Zingsem J, Strohscheer I, Schwaner I, Oettle H, et al. Hematopoietic rescue after high-dose chemotherapy using autologous peripheral blood progenitor cells or bone marrow: a randomized comparison. *J Clin Oncol* 1995;13:1328-35.
- Storek J, Dawson MA, Storer B, Stevens-Ayers T, Maloney DG, Marr KA, et al. Immune reconstitution after allogeneic marrow transplantation: does the source of hematopoietic stem cells matter? *Blood* 2001;98:2900-8.
- Flowers ME, Parker PM, Johnston LJ, Matos AV, Storer B, Bensinger WI, et al. Comparison of chronic graft-versus-host disease after transplantation of peripheral blood stem cells versus bone marrow in allogeneic recipients: long term follow up of a randomized trial. *Blood* 2002;100:415-9.
- Cohen Y, Nagler A. Umbilical cord blood transplantation—how, when and for whom? *Blood Rev* 2004;18:167-79.
- Chao NJ, Emerson SG, Weinberg KI. Stem cell transplantation (cord blood transplants). *Hematology* 2004:357-71.
- Majhail NS, Brunstein CG, Wagner JE. Double umbilical cord blood transplantation. *Curr Opin Immunol* 2006;18:571-5.
- Dean M, Fojo T, Bates S. Tumor stem cells and drug resistance. *Nat Rev Cancer* 2005;5:275-84.
- Goulmy E. Human minor histocompatibility antigens. *Curr Opin Immunol* 1996;8:75-88.
- Bacigalupo A. Second EBMT workshop on reduced intensity allogeneic hematopoietic cell transplant (RI-HSCT). *Bone Marrow Transplant* 2002;29:191-5.
- Barrett AJ, Savani BN. Stem cell transplantation with reduced-intensity conditioning regimens: a review of ten years experience with new transplant concepts and new therapeutic agents. *Leukemia* 2006;20:1661-72.
- Baron F, Storb R. Hematopoietic cell transplantation after reduced-intensity conditioning for older adults with acute myeloid leukemia in complete remission. *Curr Opin Hematol* 2007;14: 145-51.

The authors thank Dana Villines, MA, Senior Research Specialist, Department of Oral Medicine and Diagnostic

22. Shapira MY, Tsigotis P, Resnick IB, Or R, Abdul Hai A, Slavin S. Allogeneic hematopoietic stem cell transplantation in the elderly. *Crit Rev Oncol Hematol* 2007;64:49-63.
23. Mathé G. Lessons from past experience in cancer immunotherapy and their application to cancer and AIDS treatment and prophylaxis. *Biomed Pharmacother* 1989;8:551-61.
24. Luznik L, Fuchs EJ. Donor lymphocyte infusions to treat hematologic malignancies in relapse after allogeneic blood or marrow transplantation. *J Cancer Control* 2002;9:123-37.
25. Marijt E, Wafelman A, van der Hoorn M, van Bergen C, Bongarts R, van Luxemburg-Heijs S, et al. Phase I/II feasibility study evaluating the generation of leukemia-reactive cytotoxic T lymphocyte lines for treatment of patients with relapsed leukemia after allogeneic stem cell transplantation. *Haematologica* 2007;92:72-80.
26. Kennedy-Nasser AA, Bollard CM. T Cell therapies following hematopoietic stem cell transplantation: surely there must be a better way than DLI? *Bone Marrow Transplant* 2007;40:93-104.
27. Bellm LA, Epstein JB, Rose-Ped A, Martin P, Fuchs HJ. Patient reports of complications of bone marrow transplantation. *Support Care Cancer* 2000;8:33-39.
28. Sonis ST, Oster G, Fuchs H, Bellm L, Bradford WZ, Edelsberg J. Oral mucositis and the clinical and economic outcomes of hematopoietic stem-cell transplantation. *J Clin Oncol* 2001;19:2201-5.
29. Elting LS, Avritscher EB, Cooksley CD, Cardenas-Turanas M, Garden AS, Chamber MS. Psychosocial and economic impact of cancer. *Dent Clin North Am* 2008;52:231-52.
30. Sonis ST, Elting LS, Keefe D, Peterson DE, Schubert MM, Hauer-Jensen M, et al., Mucositis Study Section of the Multinational Association for Supportive Care in Cancer, International Society for Oral Oncology. Perspectives on cancer therapy-induced mucosal injury: pathogenesis, measurement, epidemiology, and consequences for patients. *Cancer* 2004;100(Suppl):1995-2025.
31. Wardley AM, Jayson GC, Swindell R, Morgenstern GR, Chang J, Bloor R, et al. Prospective evaluation of oral mucositis in patients receiving myeloablative conditioning regimens and hematopoietic progenitor treatment. *Br J Hematol* 2000;110:292-9.
32. Robien K, Schubert MM, Bruemmer B, Lloid ME, Potter JD, Ulrich C. Predictors of oral mucositis in patients receiving hematopoietic cell transplants for chronic myelogenous leukemia. *J Clin Oncol* 2004;22:1268-75.
33. Cutler C, Li S, Kim HT, Laglenne P, Hoffmeister L, et al. Mucositis after allogeneic hematopoietic stem cell transplantation; a cohort study of methotrexate and nonmethotrexate containing graft-versus-host disease prophylaxis regimens. *Biol Blood Marrow Transplant* 2005;11:383-8.
34. Vela-Ojeda J, Garcia-Ruiz Esparza MA, Tripp-Villanueva F, Ayala-Sanchez M, Delgado-Lamas JL, Garces-Ruiz O, et al. Allogeneic peripheral blood stem cell transplantation using reduced-intensity versus myeloablative conditioning regimens for the treatment of leukemia. *Stem Cells Devel* 2004;13:571-8.
35. Holmberg LA. Blood and marrow transplantation. in: Wingard JR, Bowden RA, editors. *Management of infection in oncology patients*. London, UK: Martin Dunitz; 2003: pp. 37-49.
36. Greenberg MA, Cohen SG, McKittrick JC, Cassileth PA. The oral flora as a source of septicemia in patients with acute leukemia. *Oral Surg Oral Med Oral Pathol Oral Radiol Endod* 1982;53:32-6.
37. Heimdahl A, Mattson T, Dahllöf G, Lönnquist B, Ringden O. The oral cavity as a portal of entry for early infections in patients treated with bone marrow transplantation. *Oral Surg Oral Med Oral Pathol Oral Radiol Endod* 1989;68:711-6.
38. Baquiro F, Fernandez J, Dronda F, Erice A, Perz de Oteiza J, Requira JA, Reig M. Capnophilic and anaerobic bacteremia in neutropenic patients: an oral source. *Rev Infect Dis* 1990;2(Suppl 2):S157-60.
39. Laine PO, Lindqvist JC, Pyrhönen SO, Strand-Pettinen IM, Teerenhovi LM, Meurman JH. Oral infection as a reason for febrile episodes in lymphoma patients receiving cytostatic drugs. *Eur J Cancer B Oral Oncol* 1992;28B:103-7.
40. Ruescher TJ, Sodeifi A, Scrivani SJ, Kaban LB, Sonis ST. The impact of mucositis on alpha-hemolytic streptococcal infection in patients undergoing autologous bone marrow transplantation for hematologic malignancies. *Cancer* 1998;82:2275-81.
41. Costa SF, Micelli MH, Anaissie EJ. Mucosa or skin as a source of coagulase-negative staphylococcal bacteraemia? *Lancet Infect Dis* 2004;4:278-86.
42. Epstein JB, Chow AW. Oral complication associated with immunosuppression and cancer therapies. *Infect Dis Clin North Am* 1999;13:901-23.
43. Raber-Durlacher JE, Epstein JB, Raber J, van Dissel JT, van Winkelhoff AJ, Guiot HF, van der Velden U. Periodontal infection in cancer patients treated with high-dose chemotherapy. *Support Care Cancer* 2002;10:466-73.
44. Wandt H, Frank M, Ehnninger G, Schneider C, Brack N, Daoud A, et al. Safety and cost effectiveness of a  $10 \times 10^9/L$  trigger for prophylactic platelet transfusions compared with the traditional  $20 \times 10^9/L$  trigger: a prospective comparative trial in 105 patients with acute myeloid leukemia *Blood* 1998;91:3601-6.
45. Ferrara JML, Deeg HJ, Burakoff SJ. *Graft-vs-host disease*. 2nd ed. New York: Marcel Dekker; 1997. p. 525-59.
46. Deeg JH, Antin JH. The clinical spectrum of acute graft-versus-host disease. *Semin Hematol* 2006;43:24-31.
47. Filipovich AH, Weisdorf D, Pavletic S, Socie G, Wingard JR, Lee SJ, et al. National Institutes of Health consensus development project on criteria for clinical trials in chronic graft-versus-host disease: I. Diagnosis and staging working group report. *Biol Blood Marrow Transplant* 2005;12:945-56.
48. Woo SB, Lee SJ, Schubert MM. Graft-vs-host disease. *Crit Rev Oral Biol Med* 1997;8:201-16.
49. Ferrara JL, Reddy P. Pathophysiology of graft-versus-host disease. *Semin Hematol* 2006;43:3-10.
50. Schubert MM, Correa ME. Oral graft-versus-host disease. *Dent Clin North Am* 2008;52:79-109.
51. Pavletic SZ, Lee SJ, Socie G, Vogelsang G. Chronic graft-versus-host disease: implications of the National Institutes of Health consensus development project on criteria for clinical trials. *Bone Marrow Transplant* 2006;38:645-51.
52. Baird K, Pavletic SZ. Graft versus host disease. *Curr Opin Hematol* 2006;13:226-35.
53. Schultz KR, Miklos DB, Fowler D, Cooke K, Shizuru J, Zorn E, et al. Toward biomarkers for chronic graft-versus-host disease: National Institutes of Health consensus development project on criteria for clinical trials in chronic graft-versus-host disease III. Biomarker Working Group report. *Biol Blood Marrow Transplant* 2006;12:126-37.
54. Couriel D, Carpenter PA, Cutler C, Bolanos-Meade J, Treister NS, Gea-Banacloche J, et al. Ancillary therapy and supportive care of chronic graft-versus-host disease: National Institutes of Health consensus development project on criteria for clinical trials in chronic graft-versus-host disease V: Ancillary Therapy and Supportive Care Working Group report. *Biol Blood Marrow Transplant* 2006;12:375-96.
55. Baron F, Little MT, Storb R. Kinetics of engraftment following allogeneic hematopoietic stem cell transplantation with reduced-intensity or nonmyeloablative conditioning. *Blood Rev* 2005;19:153-64.
56. Barrett J. Improving outcome of allogeneic stem cell transplan-

- tation by immunomodulation of the early post-transplant environment. *Curr Opin Immunol* 2006;18:592-8.
57. Elad S, Shapira MY, McNeal S, Or R, Garfunkel AA, Hirschhorn A, et al. Oral effects of nonmyeloablative stem cell transplantation: a prospective observational study. *Quintessence Int* 2008;39:673-8.
  58. Larsen J, Nordstöm G, Ljungman P, Gardulf A. Factors associated with poor general health after stem-cell transplantation. *Support Care Cancer* 2007;15:849-57.
  59. Nieuw van Amerongen A, Veerman EC. Saliva—the defender in the oral cavity. *Oral Dis* 2002;8:12-22.
  60. Epstein JB, Tsang AH, Warkentin D, Ship JA. The role of salivary function in modulating chemotherapy-induced oropharyngeal mucositis: a review of the literature. *Oral Surg Oral Med Oral Pathol Oral Radiol Endod* 2002;94:39-44.
  61. Imanguli MM, Atkinson J, Harvey KE, Hoehn GT, Ryu O, Wu T, et al. Changes in salivary proteome following allogeneic hematopoietic stem cell transplantation. *Exp Hematol* 2007;35:184-92.
  62. Marinone MG, Rizzoni D, Ferremi P, Rossi G, Izzi T, Brusotti C. Late taste disorders in bone marrow transplantation: clinical evaluation with taste solutions in autologous and allogeneic bone marrow recipients. *Haematologica* 1991;76:519-22.
  63. Adès L, Guardiola P, Socié P. Second malignancies after allogeneic hematopoietic stem cell transplantation: new insights and current problems. *Blood Rev* 2002;16:135-46.
  64. Elad S, Meyerowitz C, Shapira MY, Glick M, Bitan M, Amir G. Oral posttransplantation lymphoproliferative disorder: an uncommon site for an uncommon disorder. *Oral Surg Oral Pathol Oral Radiol Endod* 2008;105:59-64.
  65. Curtis RE, Rowlings PA, Deeg HJ, Shriner DA, Socié G, Travis LB, et al. Solid cancers after bone marrow transplantation. *N Engl J Med* 1997;336:897-04.
  66. Demarosi F, Lodi Giovanni, Carrassi A, Soligo D, Sardella A. Oral malignancies following HSCT: graft versus host disease and other risk factors. *Oral Oncol* 2005;41:865-77.
  67. Schulte CM, Beelen DW. Avascular osteonecrosis after allogeneic hematopoietic stem cell transplantation: diagnosis and gender matter. *Transplantation* 2004;78:1055-63.
  68. Migliorati CA, Casiglia J, Epstein JB, Jacobsen PL, Siegel MA, Woo S-B. Managing the care of patients with bisphosphonate-associated osteonecrosis: an American Academy of Oral Medicine position paper. *J Am Dent Assoc* 2005;136:1658-68.
  69. National Cancer Institute. Oral complication of chemotherapy and head/neck radiation PDQ. Bethesda, MD: National Institutes of Health. Available at: [http://www.nci.nih.gov/cancerinfo/pdq/supportive\\_care/oral\\_complications/healthprofessional](http://www.nci.nih.gov/cancerinfo/pdq/supportive_care/oral_complications/healthprofessional). Accessed Sept 10, 2008.
  70. Westbrook SD, Paunovich ED, Freytes CO. Adult hemopoietic stem cell transplantation. *J Am Dent Assoc* 2003;134:1224-31.
  71. Elad S, Thierer T, Bitan M, Shapira MY, Meyerowitz CA. Decision analysis: the dental management of patients prior to hematology cytotoxic therapy or hematopoietic stem cell transplantation. *Oral Oncol* 2008;44:37-42.
  72. Barker GJ. Current practices in the oral management of the patient undergoing chemotherapy or bone marrow transplantation. *Support Care Cancer* 1999;7:17-20.
  73. Keefe DM, Schubert MM, Elting LS, Sonis ST, Epstein JB, Raber-Durlacher JE, et al. Mucositis Study Section, Multinational Association of Supportive Care in Cancer and International Society for Oral Oncology. Updated clinical practice guidelines for the prevention and treatment of mucositis. *Cancer* 2007;109:820-31.
  74. Spielberger R, Stiff P, Bensinger W, Gentile T, Weisdorf D, Kewalramani T, et al. Palifermin for oral mucositis after intensive therapy for hematologic cancers. *N Engl J Med* 2004;351:2590-8.
  75. Galbraith LK, Bailey D, Kelly L, Rehn K, Spear S, Steinle C, et al. Treatment for alteration in oral mucosa related to chemotherapy. *Pediatr Nurs* 1991;17:233-6.
  76. Epstein JB, Hancock PJ, Nantel S. Oral candidiasis in hematopoietic cell transplantation patients: an outcome-based analysis. *Oral Surg Oral Med Oral Pathol Oral Radiol Endod* 2003;96:154-63.
  77. Epstein JB, Truelove EL, Hanson-Huggins K, Mancl LA, Chen A, Press OW, et al. Topical polyene antifungals in hematopoietic cell transplant patients: tolerability and efficacy. *Support Care Cancer* 2004;12:517-25.
  78. Epstein JB, Phillips N, Parry J, Epstein MS, Nevill T, Stevenson-Moore P. Quality of life, taste, olfactory and oral function following high-dose chemotherapy and allogeneic hematopoietic cell transplantation. *Bone Marrow Transplant* 2002;30:785-92.
  79. Schubert MM, Peterson DE, Lloid ME. Oral complications. In: Thomas ED, Blume KG, Forman SJ, editors. *Hematopoietic cell transplantation*. 2nd ed. Malden (MA): Blackwell Science; 1999. p. 751-63.
  80. Epstein JB, Epstein JD, Epstein MS, Oien H, Truelove EL. Management of pain in cancer patients with oral mucositis: follow-up of multiple doses of doxepin oral rinse. *J Pain Symptom Manage* 2007;33:111-4.
  81. Atkinson JC, Grisius M, Massey W. Salivary hypofunction and xerostomia. *Dent Clin North Am* 2005;49:309-26.
  82. Dahlöf G. Craniofacial growth in children treated for malignant diseases. *Acta Odont Scand* 1998;56:378-82.
  83. Uderzo C, Fraschini D, Balduzzi A, Galimberti S, Arrigo C, Biagi E, et al. Long-term effects of bone marrow transplantation on dental status in children with leukaemia. *Bone Marrow Transplant* 1997;20:865-9.
  84. Hölttä P, Hovi L, Saarinen-Pihkala UM, Peltola J, Alaluusua S. Disturbed root development of permanent teeth after pediatric stem cell transplantation. Dental root development after SCT. *Cancer* 2005;103:1484-93.
- Reprint requests:*  
Dr. Joel B. Epstein  
Department of Oral Medicine and Diagnostic Sciences  
College of Dentistry  
University of Illinois  
801 South Paulina Street  
Chicago, IL 60612  
[jepstein@uic.edu](mailto:jepstein@uic.edu)