



Institut Pasteur

Microbes and Infection xx (2016) 1–7



www.elsevier.com/locate/micinf

Review

Dental screening of medical patients for oral infections and inflammation: consideration of risk and benefit

Delphine Maret^{a,b,*}, Ove A. Peters^c, Emmanuelle Vigarios^d, Joel B. Epstein^e,
Lucas van der Sluis^f

^a Laboratoire Anthropologie Moléculaire et Imagerie de Synthèse (AMIS), UMR 5288, CNRS, Toulouse, France

^b Faculté de Chirurgie Dentaire, Université Paul Sabatier, Centre Hospitalier Universitaire, Toulouse, France

^c Department of Endodontics, University of the Pacific, Arthur A Dugoni, School of Dentistry, San Francisco, CA, USA

^d Oral Oncology Department, Comprehensive Cancer Center Institut Claudius-Regaud, Institut Universitaire du Cancer, Toulouse, France

^e Department of Surgery, Cedars-Sinai Medical Center, Los Angeles, CA, USA

^f Center of Dentistry and Oral Hygiene, University Medical Center Groningen, The Netherlands

Received 12 August 2016; accepted 9 October 2016

Available online ■ ■ ■

Abstract

The primary purpose of preoperative dental screening of medical patients is to detect acute or chronic oral conditions that may require management prior to planned medical interventions. The aim of this communication is to discuss the background of preoperative dental screening and the link between dental pathologies and systemic diseases.

© 2016 Institut Pasteur. Published by Elsevier Masson SAS. All rights reserved.

Keywords: Oral inflammatory diseases; Dental diseases; Medical interventions; Infection control

1. Introduction

Chronic oral diseases, such as dental caries and periodontitis, are among the most prevalent microbial diseases in man [1,2]. However, the close connection between dental health and outcomes of medical management may be underreported and underappreciated in the medical setting. Yet, the importance of the state of the oral cavity for overall health is a far from recent idea. The mouth has been considered to reflect general health since antiquity. In the fifth century BCE, Hippocrates had already observed that suppressing sites of infection in the mouth reduced some types of joint pain [3].

Preoperative dental screening may be requested by physicians, including anesthesiologists, cardiologists, oncologists and orthopedic surgeons, before certain medical interventions [4,5], for example, elective cardiac or orthopedic surgery, cancer therapy and hematopoietic and organ transplantation. The examination is requested for all patients, whatever their general state of health. In practice, a physician refers a patient to a dentist so that sites of trauma and infection can be identified. However, in some cases, the care and follow-up of dental pathologies may last up to 6 months before the condition can be considered cured or approaches that include extraction may be chosen to provide definitive therapy. Considerations include the urgency of medical management, the presence of acute or chronic dental disease, and the impact of the envisaged medical therapy upon future dental treatment. For example, in head and neck radiation therapy, future dental treatment is limited by the cancer therapy provided and comprehensive dental care and prevention is needed prior to

* Corresponding author. Faculté de Chirurgie Dentaire, Université Paul Sabatier, Centre Hospitalier Universitaire, Toulouse, France.

E-mail address: delphine_maret@yahoo.fr (D. Maret).

radiation therapy within the high dose radiation fields [6]. Considerations of the dental treatment plan may require consultation and coordination with the medical provider to balance the urgency of medical care, dental care and dental prevention. There is limited evidence in head and neck cancer patients that risk of osteoradionecrosis may be reduced by management of pre-existing dental foci [6]. Dental treatment of foci of infection prior to chemotherapy including hematopoietic stem cell transplantation is associated with reduced febrile episodes [7]. In addition, some confusion exists in the search for sites of oral infection. Treatment and follow-up for acute pathologies are not the same as for chronic ones. Fear of the presence of infection should not favor the extraction of a tooth that could be managed by therapy and saved, but must be balanced by the prognosis of success of treatment of the focus of infection, if definitive removal of a site of infection is mandatory. There is no clear evidence of its benefits and effectiveness to date, in particular for the screening of asymptomatic dental foci of infection or disease. Consequently, preoperative screening protocols are not evidence-based and clear guidelines or inclusion criteria concerning the nature of the patient evaluation and of oral diseases are lacking. This, in turn, leads to communication challenges between health care professionals and patients to ensure that medically necessary oral care is provided. However, awareness of the link between some chronic oral diseases and systemic diseases has increased the attention paid to diagnosing and treating these oral diseases, and thus has led to improvement in the oral and systemic health of patients [8,9]. So, although there is no scientific proof of the need for preoperative screening in all patients, it is nevertheless important to note the associations between chronic oral diseases and systemic diseases and to determine if dental pathologies impact systemic diseases. This communication aims to assess the scientific background of preoperative dental screening and to discuss evidence of the role of dental pathologies that are linked with several systemic diseases.

2. What is the rationale and scientific background of preoperative dental screening?

The purpose of preoperative dental screening is to detect chronic or acute oral infections including caries, periodontitis, pericoronitis, peri-implantitis and apical periodontitis [4,5] and to establish oral/dental preventive protocols appropriate for the oral status, medical condition and medical management. The preoperative clinical dental examination [10] includes extra- and intra-oral tissues: the head and neck (masses, asymmetry, lymph nodes, cranial nerves), oral mucosa (lesions), salivation and teeth or dental implants, with their surrounding supporting tissue (periodontal tissue). More than 500 species of microorganisms are found in the mouth and the microorganisms found in biofilm on the teeth contain around 10^{11} microorganisms/mg [11]. In cases of poor oral hygiene, this number may be multiplied by a factor of 2–10 [12]. Oral microorganisms that cannot adhere to a surface are transported by salivary flow out of the mouth and down the digestive tract

[13]. Oral microorganisms can enter the circulation and cause bacteremia. In daily life, this happens continuously, for example after tooth brushing or chewing [14] but this bacteremia is typically short-lived, on the order of seconds or up to few minutes [15]. Dental procedures may also induce bacteremia, which may include larger numbers of organisms, but this has not been clearly associated with a higher health risk [16]. Furthermore, the chance of bacteremia arising from normal, everyday life is 1000–8000 times more frequent than that due to any dental treatment procedure [17]. It is thus very difficult to determine the origin of the bacteremia and causality.

Oral infections, including gingivitis and periodontitis, will increase the bacterial load or can harbor more specific microbial species than those normally present [18]. However, oral microorganisms that are detected at distant sites, like atherosclerotic plaques or biofilms (the cause of endocarditis), are normally found in the mouth and are not typically related to oral disease [19]. These considerations may be more important in medically complex patients. The four landmark dental infections are dental caries, periodontitis, peri-implantitis and apical periodontitis [4,5]. These diseases are typically chronic and caused by an oral biofilm where microorganisms are encased in a matrix that protects them from external attack, allowing them to grow and flourish [13]. Chronic infection is caused by microorganisms organized in a biofilm in contrast to an acute infection, which is caused by planktonic microorganisms, which can easily spread throughout the body [20]. Normally, the clinical differentiation between acute and chronic is based upon symptoms related to acute infection, including pain and swelling. Therefore, acute infections are more easily identified on screening. Once the infection has been identified, treatment planning can begin. Although there is no tangible scientific proof of the importance of carrying out preoperative screening for all patients, the literature reports associations between chronic oral diseases and systemic diseases [8,9,21], which would probably justify preoperative screening for patients presenting these pathologies. Two oral pathologies associated with systemic diseases are periodontitis and apical periodontitis.

3. Association between chronic dental diseases and systemic diseases

Periodontal and pulpal inflammation demonstrate similar patterns of development: initially, both exhibit signs of soft-tissue inflammation caused by an infection with mixed flora of oral commensals [22]. At a later stage, the two pathologic processes culminate in bone resorption (vertical bone-loss or apical periodontitis, respectively) [22]. Similar events occur in the host defense in both conditions, such as upregulation of inflammatory cytokines that initiate and sustain the inflammatory response, ultimately culminating in bone resorption [22].

In a study related to endodontic disease, Segura-Egea et al. [9] described three important similarities between chronic periodontal and endodontic inflammatory processes [23]. They noted that:

1. Both are chronic infections of the oral cavity;
2. Both are polymicrobial infections sharing a common microbiota with a predominance of Gram-negative anaerobic bacteria [24];
3. Cytokine levels may be released systemically from acute and chronic manifestations of both disease processes for example increased concentrations of inflammatory mediators have been detected both in the gingival crevicular fluid of subjects with periodontal disease and in the periapical tissues of endodontically involved teeth [9,25,26].

3.1. Periodontitis

Periodontitis or periodontal disease is a biofilm-induced, predominantly chronic, inflammatory disease of the periodontium, the tissues supporting the teeth, which results in localized alveolar bone resorption associated with plaque adhering to root surfaces; it is the most common reason for tooth loss [1]. Periodontitis is minimally symptomatic or asymptomatic until advanced and is often occult in presentation, yet constitutes a significant condition with risk of infection, which may require surgical care in the future for management. The prevalence of periodontitis in the USA is estimated at between 50 and 70% [27]. Periodontitis has been described as a microbial shift disease (from mostly Gram-positive to mostly Gram-negative species) [28]. However, the cause of this shift is unknown. The goal of periodontal treatment is to restore the relationship between periodontal tissue and biofilm [27]. The screening procedure for periodontitis is specific and is reliable but management of the disease requires patient cooperation. Treatment and healing time depend strongly on the severity of the disease and may reach several months. Advanced forms may require extraction of the teeth involved.

3.1.1. Association between periodontitis and systemic diseases

Since the 1990s the potential relationship between periodontitis and systemic health and disease has gained increasing recognition [29] and ‘periodontal medicine’ is now considered as a distinct field. Systemic diseases such as diabetes mellitus [30,31], coronary heart disease and acute myocardial infarction [29–35], preterm low birth weight [36,37], respiratory diseases [38], metabolic syndrome [39], early loss of memory and capacity for calculation [40] and rheumatoid arthritis [41] have been reported to be associated with periodontal disease. In all the pathologies that seem to have a connection with periodontitis, infection is a recognized etiopathogenic factor, whence the hypothesis that bacteremia induced by the periodontitis could be directly or indirectly responsible for the occurrence or aggravation of pathologies in other parts of the body. It is now accepted that certain inflammatory mechanisms are common to systemic diseases and periodontitis and that the latter disease contributes to systemic inflammation, a major role being played by proinflammatory cytokines (see Fig. 1) [42].

The continuous presence of periodontal bacteria reactivates the inflammatory response by releasing active molecules (endotoxins, LPS, bacterial products) and resulting in the release of mediators of inflammation (IL, TNF α , CRP, etc.) capable of causing serious changes in the behavior of numerous cells [42].

3.1.2. Diabetes mellitus

The relation between periodontitis and diabetes is thought to be bi-directional [43]. Diabetes is a known risk factor for periodontitis [44]. According to the WHO, periodontal disease is the 6th most common complication of diabetes [45]. In patients with uncontrolled or poorly controlled diabetes, whatever the type, the prevalence of periodontitis is observed to be 4 times higher than in the general population [46] and the number of subjects with lost teeth is higher than in non-diabetics [47]. There is also increased prevalence of severe forms of periodontitis, with greater attachment loss (2.7 mm vs. 25 mm) in diabetics than non-diabetics [48]. Darre et al. [49] have shown that the presence of periodontitis can play a part in the glycemic imbalance of diabetic patients and may complicate diabetic control [49]. Periodontal treatment seems to affect blood glucose, with a decrease in the glycated hemoglobin concentration (HbA1c) [50].

3.1.3. Cardiovascular diseases

Periodontitis and cardiovascular disease are chronic diseases with an inflammatory component and share certain risk factors such as sex, age, stress, tobacco use, diabetes, obesity (BMI > 30 kg/m²) or socio-economic status [51]. Other risk factors specific to cardiovascular disease share responsibility for the start and evolution of pathology due to atheroma: hypercholesterolemia (LDL > 100 mg/dl), sedentarity, arterial hypertension or raised C-reactive protein. Slade et al. [52] showed elevated plasma CRP levels (atheroma risk factor) in presence of advanced periodontal disease. Tonetti et al.’s work [53] indicates decreased cardiovascular risk (improvement in endothelial function and decrease in inflammation markers) in cases of intensive, purely mechanical, periodontal treatment.

3.1.4. Preterm-low birth weight

Nabet et al. [54] have shown that the association between periodontitis and premature delivery appears to be influenced by the socio-economic status of the pregnant woman. Generalized periodontitis is correlated with a risk factor for premature delivery due to pre-eclampsia. The association would increase with the extent of the periodontitis [54].

3.1.5. Rheumatoid polyarthritis

The relation between periodontitis and rheumatoid polyarthritis appears to operate in both directions and to be independent of risk factors such as alcohol, tobacco, poor hygiene, socioeconomic status, excess weight and obesity [41].

3.1.6. Respiratory diseases

Recent studies have brought out an association between periodontitis and certain respiratory diseases: bacterial pneumonia and chronic obstructive bronchopneumopathy [55].

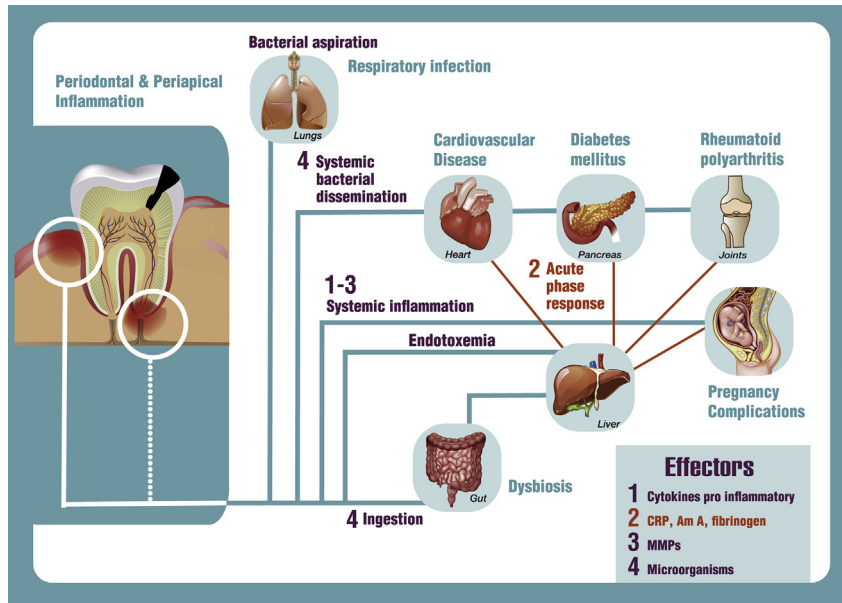


Fig. 1. Potential pathways for associations between oral inflammation (e.g. marginal and periapical periodontitis) with systemic diseases as well as potential associations between oral and systemic diseases.

3.1.7. Cognitive function

Recently, the literature has suggested a link between periodontitis and cognitive function [40].

3.2. Apical periodontitis

Apical periodontitis (AP) is an endodontic infection. AP is defined as an oral inflammatory disease caused by the presence of biofilm close to or in the root canal system or at the outside around the root apex [56]. Due to the complex anatomy of the root canal system, complete removal of the biofilm may not be possible. The prevalence in a European population was reported to be around 65% [57]. If AP persists, cancellous periapical bone around the tip of the root, and also the cementum layer covering the root, may be resorbed and replaced by inflammatory tissue. In a later stage, the cortical bone of the jaw is affected and it is then that the lesion becomes visible on a dental radiograph. AP often develops without symptoms. In contrast to the other dental diseases, asymptomatic AP can only be screened with the help of radiographs (i.e. 2D periapical and panoramic radiographs, and 3D imaging). However, periapical radiographs, and particularly panoramic radiographs, may significantly underestimate the incidence of AP, with a false negative value of around 40% [58,59]. Consequently, the periapical radiograph is an inefficient tool to screen for AP. In contrast, CBCT imaging enables AP to be detected more efficiently than with periapical radiographs [59] and, therefore, may provide a more effective way to screen for AP [60]. But be careful with over diagnosis. With CBCT use, significant biological impact and financial cost are necessary to evaluate in further studies. Fig. 2 shows an example of an incidental finding of asymptomatic AP.

If the tooth is treated endodontically, healing may take up to one year to confirm resolution, and, therefore, if definitive

treatment is needed, extraction may be considered [58]. Furthermore, mature fibrous tissue may replace the periapical tissue upon healing [apical scar] and present on imaging as an apical radiolucency. Definitive therapy may require extraction of the teeth involved.

3.2.1. Association between apical periodontitis and systemic diseases

At present, the question of whether infection can spread from a root canal to distant parts of the body has not been settled (except in the case of systemically compromised patients). Evidence that such is the case is inconclusive but, conversely, there is no clear proof that endodontic infections remain confined to the primarily affected area [61].

There is evidence associating diabetes mellitus with a higher prevalence of AP, more extensive periapical osteolytic lesions, greater likelihood of asymptomatic periapical infections and delay/arrest of periapical repair.

Poor oral health and endodontic infections are known to be associated with cardiovascular diseases [8], and endodontic infection appears to be associated with initial endothelial damage. Patients receiving intravascular or intracardiac prostheses, requiring surgery for their placement, are at risk for the development of infection and a preoperative dental (including endodontic) evaluation is recommended. Dental and endodontic treatment, completed before surgery if possible, may decrease the incidence of late prosthetic valve endocarditis but perioperative antibiotic prophylaxis remains necessary in these patients [62].

The possible relationship between other general diseases and AP has been the subject of several recent studies. Diseases such as hypertension, osteoporosis, chronic liver disease or inherited coagulation disorders, can have marked effects on wound healing and there is evidence of their association with

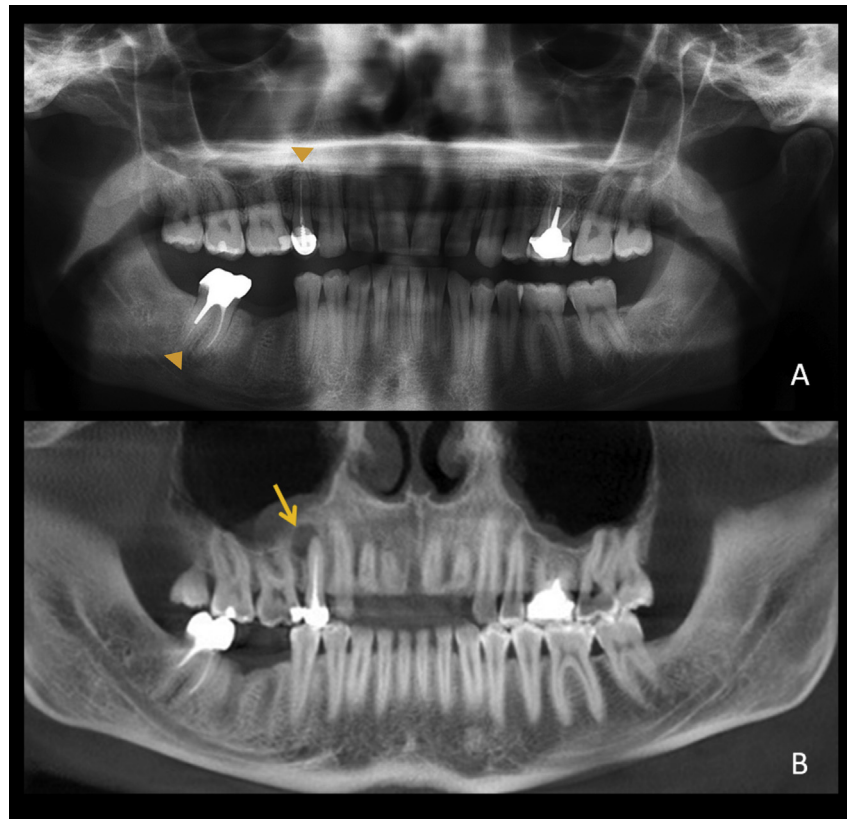


Fig. 2. Comparison of conventional radiographs and cone-beam tomography (CBCT) in the detection of intraosseous bone changes. Conventional imaging represents a summation of all radiodensities in the path of the X-ray beam, while tomographic techniques represent local radiodensities and give an overall more accurate representation of osseous changes. A: Panoramic radiograph shows an apparently normal periapical area of the upper right premolar and the lower right second molar (arrowheads). Note that both teeth are root canal-treated (root canal filling evident as radiodense white lines). B: A reformatted CBCT image of the same patient shows an apical radiolucency (arrow) associated with the upper premolar but not the lower molar.

impaired innate immune responses. The lack of research into possible connections between endodontic infection processes and systemic diseases may have resulted in a failure to reveal the potential risk of retaining teeth with chronic AP, the real health advantages of endodontic treatment for patients, and thus its importance to physicians and dentists [9].

4. Discussion and point of view

Our aim has been to initiate a debate regarding oral screening. Because associations between chronic oral and non-oral diseases are established, it may be reasonable to use selective dental screening based on the risk perceived for the individual patient. Treatment and follow-up for acute pathologies are not the same as for chronic diseases. Fear of the presence infection should not favor the extraction of a tooth that could be managed by therapy and saved, particularly as, after the therapy for the main pathology, it will be necessary to offer the patient a solution for tooth loss and to maintain function. This may lead to compromised oral function and possible additional costs or procedures with additional risk that could have been avoided. For example, CBCT is more accurate than standard radiography [59,60] so, if we really think it is important to diagnose and treat chronic AP, should

we use a CBCT scan? Do we want to scan for chronic AP with a goal of preventing possible bacteremia? It is important to weigh the benefit a patient may gain from the diagnostic efficacy of CBCT imaging against the cost and the risk the irradiation presents for this individual patient and potential outcomes of an intervention that may result from a finding on CBCT, or of lack of intervention. Further research should help to develop a consensus on whether AP needs to be detected and treated before medical interventions. Preoperative screening and treatment of acute dental disease is possible within a rather short timeframe, with treatment defined on the basis of the dental and medical status. The screening protocol for acute dental disease is relatively simple and may allow effective treatment to be given and preventive protocols to be instituted, reducing the risk of infection due to planktonic microorganisms. Because chronic oral diseases may be progressive and cumulative and consequently can become more complex over time [63], research that addresses the impact of chronic infection due to oral organisms is required. This may be of importance in medically complex patients, particularly those in whom the medical condition or its management will prevent future dental intervention. The prevalence of chronic dental disease is high and it is often difficult to effectively screen for such diseases and/or heal them within a relatively

short timeframe or without CBCT scans for AP. Therefore the preoperative dental screening may not completely fulfill its purpose. Continuous cooperation of the patient in the form of oral hygiene is indispensable. Oral and dental screening is likely to report symptomatic conditions that require treatment but asymptomatic and chronic disease may not be detected. We believe it is important to make a clear distinction between acute or chronic dental disease in the debate regarding oral screening. When a healthcare professional requests preoperative screening, it is anticipated that acute dental disease will be detected and managed. However, the identification and effect of treatment of chronic conditions are not defined. Guidelines should be developed and improved, based on continued observation and documentation, and the accumulation of evidence-based data. This is likely to require more cohort studies and randomized clinical trials.

Conflicts of interest

The authors declare that they have no conflict of interest.

Acknowledgments

The authors thank Jacques Treil, Paul Monsarrat and Auriane Martegoutte for their useful guidance and Susan Becker for language revision.

References

- [1] Pihlstrom BL, Michalowicz BS, Johnson NW. Periodontal diseases. *Lancet Lond Engl* 2005;366(9499):1809–20.
- [2] Selwitz RH, Ismail AI, Pitts NB. Dental caries. *Lancet Lond Engl* 2007;369(9555):51–9.
- [3] Tsoukanelis AS. Hippocrates and the mouth. *J Hist Dent* 1998;46(1):25–30.
- [4] Yasny JS, White J. Dental considerations for cardiac surgery. *J Card Surg* 2009;24(1):64–8.
- [5] Barrington JW, Barrington TA. What is the true incidence of dental pathology in the total joint arthroplasty population? *J Arthroplasty* 2011;26(6 Suppl):88–91.
- [6] Schuurhuis JM, Stokman MA, Witjes MJH, Dijkstra PU, Vissink A, Spijkervet FKL. Evidence supporting pre-radiation elimination of oral foci of infection in head and neck cancer patients to prevent oral sequelae. A systematic review. *Oral Oncol* 2015;51(3):212–20.
- [7] Elad S, Thierer T, Bitan M, Shapira MY, Meyerowitz C. A decision analysis: the dental management of patients prior to hematology cytotoxic therapy or hematopoietic stem cell transplantation. *Oral Oncol* 2008;44(1):37–42.
- [8] Cotti E, Mercuro G. Apical periodontitis and cardiovascular diseases: previous findings and ongoing research. *Int Endod J* 2015;48(10):926–32.
- [9] Segura-Egea JJ, Martín-González J, Castellanos-Cosano L. Endodontic medicine: connections between apical periodontitis and systemic diseases. *Int Endod J* 2015;48(10):933–51.
- [10] Hayes PA, Fasules J. Dental screening of pediatric cardiac surgical patients. *ASDC J Dent Child* 2001;68(4):255–8. 228-9.
- [11] Li X, Kolltveit KM, Tronstad L, Olsen I. Systemic diseases caused by oral infection. *Clin Microbiol Rev* 2000;13(4):547–58.
- [12] Loesche WJ. Association of the oral flora with important medical diseases. *Curr Opin Periodontol* 1997;4:21–8.
- [13] Kolenbrander PE, Palmer RJ, Periasamy S, Jakubovics NS. Oral multi-species biofilm development and the key role of cell-cell distance. *Nat Rev Microbiol* 2010;8(7):471–80.
- [14] Berbari EF, Osmon DR, Carr A, Hanssen AD, Baddour LM, Greene D, et al. Dental procedures as risk factors for prosthetic hip or knee infection: a hospital-based prospective case-control study. *Clin Infect Dis Off Publ Infect Dis Soc Am* 2010;50(1):8–16.
- [15] Lockhart PB, Brennan MT, Sasser HC, Fox PC, Paster BJ, Bahrani-Mougeot FK. Bacteremia associated with toothbrushing and dental extraction. *Circulation* 2008;117(24):3118–25.
- [16] Strom BL, Abrutyn E, Berlin JA, Kinman JL, Feldman RS, Stolley PD, et al. Dental and cardiac risk factors for infective endocarditis. A population-based, case-control study. *Ann Intern Med* 1998;129(10):761–9.
- [17] Roberts GJ. Dentists are innocent! « Everyday » bacteremia is the real culprit: a review and assessment of the evidence that dental surgical procedures are a principal cause of bacterial endocarditis in children. *Pediatr Cardiol* 1999;20(5):317–25.
- [18] Leishman SJ, Do HL, Ford PJ. Cardiovascular disease and the role of oral bacteria. *J Oral Microbiol* 2010;2.
- [19] Baddour LM, Wilson WR, Bayer AS, Fowler VG, Bolger AF, Levison ME, et al. Infective endocarditis: diagnosis, antimicrobial therapy, and management of complications: a statement for healthcare professionals from the Committee on Rheumatic Fever, Endocarditis, and Kawasaki Disease, Council on Cardiovascular Disease in the Young, and the Councils on Clinical Cardiology, Stroke, and Cardiovascular Surgery and Anesthesia, American Heart Association: endorsed by the Infectious Diseases Society of America. *Circulation* 2005;111(23):e394–434.
- [20] Monsarrat P, Blaizot A, Kémoun P, Ravaud P, Nabet C, Sixou M, et al. Clinical research activity in periodontal medicine: a systematic mapping of trial registers. *J Clin Periodontol* 2016;43(5):390–400.
- [21] Furukawa S, Kuchma SL, O'Toole GA. Keeping their options open: acute versus persistent infections. *J Bacteriol* 2006;188(4):1211–7.
- [22] Graves DT, Oates T, Garlet GP. Review of osteoimmunology and the host response in endodontic and periodontal lesions. *J Oral Microbiol* 2011;3:5304.
- [23] Segura-Egea J-J, Castellanos-Cosano L, Machuca G, López-López J, Martín-González J, Velasco-Ortega E, et al. Diabetes mellitus, periapical inflammation and endodontic treatment outcome. *Med Oral Patol Oral Cir Bucal* 2012;17(2):e356–361.
- [24] Siqueira JF, Rôças IN. Present status and future directions in endodontic microbiology. *Endod Top* 2014;30(1):3–22.
- [25] Caplan DJ. Epidemiologic issues in studies of association between apical periodontitis and systemic health. *Endod Top* 2004;8(1):15–35.
- [26] Caplan DJ, Chasen JB, Krall EA, Cai J, Kang S, Garcia RI, et al. Lesions of endodontic origin and risk of coronary heart disease. *J Dent Res* 2006;85(11):996–1000.
- [27] Eke PI, Dye BA, Wei L, Thornton-Evans GO, Genco RJ. CDC Periodontal Disease Surveillance workgroup: James Beck (University of North Carolina, Chapel Hill, USA), Gordon Douglass (Past President, American Academy of Periodontology), Roy Page (University of Washin. Prevalence of periodontitis in adults in the United States: 2009 and 2010. *J Dent Res* 2012;91(10):914–20.
- [28] Marsh PD. Microbial ecology of dental plaque and its significance in health and disease. *Adv Dent Res* 1994;8(2):263–71.
- [29] Seymour RA. Is gum disease killing your patient? *Br Dent J* 2009;206(10):551–2.
- [30] Katz J. Elevated blood glucose levels in patients with severe periodontal disease. *J Clin Periodontol* 2001;28(7):710–2.
- [31] Soskolne WA, Klinger A. The relationship between periodontal diseases and diabetes: an overview. *Ann Periodontol Am Acad Periodontol* 2001;6(1):91–8.
- [32] Beck J, Garcia R, Heiss G, Vokonas PS, Offenbacher S. Periodontal disease and cardiovascular disease. *J Periodontol* 1996;67(10 Suppl):1123–37.
- [33] Janket S-J, Baird AE, Chuang S-K, Jones JA. Meta-analysis of periodontal disease and risk of coronary heart disease and stroke. *Oral Surg Oral Med Oral Pathol Oral Radiol Endod* 2003;95(5):559–69.
- [34] Dörfer CE, Becher H, Ziegler CM, Kaiser C, Lutz R, Jörss D, et al. The association of gingivitis and periodontitis with ischemic stroke. *J Clin Periodontol* 2004;31(5):396–401.

- [35] Grau AJ, Becher H, Ziegler CM, Lichy C, Buggle F, Kaiser C, et al. Periodontal disease as a risk factor for ischemic stroke. *Stroke J Cereb Circ F* 2004;35(2):496–501.
- [36] Jeffcoat MK, Hauth JC, Geurs NC, Reddy MS, Cliver SP, Hodgkins PM, et al. Periodontal disease and preterm birth: results of a pilot intervention study. *J Periodontol* 2003;74(8):1214–8.
- [37] Marin C, Segura-Egea JJ, Martínez-Sahuquillo A, Bullón P. Correlation between infant birth weight and mother's periodontal status. *J Clin Periodontol* 2005;32(3):299–304.
- [38] Scannapieco FA, Bush RB, Paju S. Associations between periodontal disease and risk for nosocomial bacterial pneumonia and chronic obstructive pulmonary disease. A systematic review. *Ann Periodontol Am Acad Periodontol* 2003;8(1):54–69.
- [39] Shrestha D, Choi Y-H, Zhang J, Hazlett LJ, Merchant AT. Relationship between serologic markers of periodontal bacteria and metabolic syndrome and its components. *J Periodontol* 2015;86(3):418–30.
- [40] Noble JM, Borrell LN, Papapanou PN, Elkind MSV, Scarmeas N, Wright CB. Periodontitis is associated with cognitive impairment among older adults: analysis of NHANES-III. *J Neurol Neurosurg Psychiatry* 2009;80(11):1206–11.
- [41] Pischon N, Pischon T, Kröger J, Gülmez E, Kleber B-M, Bernimoulin J-P, et al. Association among rheumatoid arthritis, oral hygiene, and periodontitis. *J Periodontol* 2008;79(6):979–86.
- [42] Hajishengallis G. Periodontitis: from microbial immune subversion to systemic inflammation. *Nat Rev Immunol* 2015;15(1):30–44.
- [43] Chee B, Park B, Bartold PM. Periodontitis and type II diabetes: a two-way relationship. *Int J Evid Based Healthc* 2013;11(4):317–29.
- [44] Preshaw PM. Periodontal disease and diabetes. *J Dent* 2009;37(8):S575–7.
- [45] Loe H. Periodontal disease. The sixth complication of diabetes mellitus. *Diabetes Care* 1993;16(1):329–34.
- [46] Borrell LN, Burt BA, Taylor GW. Prevalence and trends in periodontitis in the USA: the [corrected] NHANES, 1988 to 2000. *J Dent Res* 2005;84(10):924–30.
- [47] Mealey BL, Oates TW. American Academy of Periodontology. Diabetes mellitus and periodontal diseases. *J Periodontol* 2006;77(8):1289–303.
- [48] Mattout C, Bourgeois D, Bouchard P. Type 2 diabetes and periodontal indicators: epidemiology in France 2002–2003. *J Periodontol Res* 2006;41(4):253–8.
- [49] Darré L, Vergnes J-N, Gourdy P, Sixou M. Efficacy of periodontal treatment on glycaemic control in diabetic patients: a meta-analysis of interventional studies. *Diabetes Metab* 2008;34(5):497–506.
- [50] Vergnes J-N, Arrivé E, Gourdy P, Hanaire H, Rigalleau V, Gin H, et al. Periodontal treatment to improve glycaemic control in diabetic patients: study protocol of the randomized, controlled DIAPERIO trial. *Trials* 2009;10:65.
- [51] Kinane DF, Lowe GD. How periodontal disease may contribute to cardiovascular disease. *Periodontol* 2000;23:121–6. 2000.
- [52] Slade GD, Offenbacher S, Beck JD, Heiss G, Pankow JS. Acute-phase inflammatory response to periodontal disease in the US population. *J Dent Res* 2000;79(1):49–57.
- [53] Tonetti MS, D'Aiuto F, Nibali L, Donald A, Storry C, Parkar M, et al. Treatment of periodontitis and endothelial function. *N Engl J Med* 2007;356(9):911–20.
- [54] Nabet C, Lelong N, Colombier M-L, Sixou M, Musset A-M, Goffinet F, et al. Maternal periodontitis and the causes of preterm birth: the case-control Epipap study. *J Clin Periodontol* 2010;37(1):37–45.
- [55] Leuckfeld I, Obregon-Whittle MV, Lund MB, Geiran O, Bjørtuft Ø, Olsen I. Severe chronic obstructive pulmonary disease: association with marginal bone loss in periodontitis. *Respir Med* 2008;102(4):488–94.
- [56] Haapasalo M, Shen Y, Ricucci D. Reasons for persistent and emerging post-treatment endodontic disease. *Endod Top* 2008;18(1):31–50.
- [57] Boucher Y, Matossian L, Rilliard F, Machtou P. Radiographic evaluation of the prevalence and technical quality of root canal treatment in a French subpopulation. *Int Endod J* 2002;35(3):229–38.
- [58] Wu M-K, Dummer PMH, Wesselink PR. Consequences of and strategies to deal with residual post-treatment root canal infection. *Int Endod J* 2006;39(5):343–56.
- [59] Estrela C, Bueno MR, Leles CR, Azevedo B, Azevedo JR. Accuracy of cone beam computed tomography and panoramic and periapical radiography for detection of apical periodontitis. *J Endod* 2008;34(3):273–9.
- [60] Pope O, Sathorn C, Parashos P. A comparative investigation of cone-beam computed tomography and periapical radiography in the diagnosis of a healthy periapex. *J Endod* 2014;40(3):360–5.
- [61] Siqueira Jr JF. Treatment of endodontic infections. London: Quintessence Publishing; 2011. p. 416.
- [62] Wilson W, Taubert KA, Gewitz M, Lockhart PB, Baddour LM, Levison M, et al. Prevention of infective endocarditis: guidelines from the American Heart Association: a guideline from the American Heart Association Rheumatic Fever, Endocarditis, and Kawasaki Disease Committee, Council on Cardiovascular Disease in the Young, and the Council on Clinical Cardiology, Council on Cardiovascular Surgery and Anesthesia, and the Quality of Care and Outcomes Research Interdisciplinary Working Group. *Circulation* 2007;116(15):1736–54.
- [63] Oral Health in America: A Report of the Surgeon General (Executive Summary) <http://www.nidcr.nih.gov/DataStatistics/SurgeonGeneral/Report/ExecutiveSummary.htm>.